

Case Report

The use of a feeding tube in the treatment of a parotid duct fistula: A case report

Ajike SO*, Omisakin OO and Ogbeifun JO

Department of Oral and Maxillofacial Surgery, Ahmadu Bello University Teaching Hospital, Zaria, Kaduna State, Nigeria.

Accepted 29 June, 2011

Parotid duct fistula is uncommon and difficult to treat. The challenges of the surgical repair of a chronic type D1(a) parotid duct fistula in a 20-year-old male patient in a poor resource setting is described and compared to previous reports. Diagnosis of fistula was confirmed clinically when the parotid was milked and while patient was eating. Repair was carried out using a feeding tube under general anesthesia six years after the sustained injury. Full recovery was achieved post-operatively with established salivary flow from the Stenson's duct. The various modalities of treatment are briefly mentioned. Trauma/laceration to the parotid and cheek/buccal region should raise a suspicion of possible parotid duct fistula.

Keywords: Fistula, parotid, duct, feeding tube, trauma

INTRODUCTION

Parotid duct fistula is uncommon. In a study by Ananthakrishnan and Parkash (1982) only 17 cases were documented over a 10 year period. The most common cause is trauma (Chadwick et al., 1979; Parekh et al., 1989), accounting for 30% of post traumatic parotid fistula and sialoceles². Other causes include operative complications, infection and malignancies (Ananthakrishnan and Parkash, 1982; Chadwick et al., 1979; Parekh et al., 1989). Sialograph (Gadodia et al., 2008) is a useful diagnostic tool in the precise localization of the transection. The treatment of parotid fistula remains controversial. Numerous methods of treatment have been documented in the literature with varying degrees of success (Chadwick et al., 1979; Heymans et al., 1999; Abramson, 1973; Ellis et al., 2004). We therefore present a case of post traumatic parotid duct fistula in a 20 year old male patient with the use of an improvised feeding tube and raising suspicion of parotid duct injury in facial trauma.

CASE REPORT

A 20-year-old male patient was referred to the Oral and Maxillofacial Clinic of the Ahmadu Bello University Teaching Hospital, Shika, Zaria, Kaduna State, Nigeria

with a history of post-traumatic left cheek fistula, sanguinous discharge of six years duration.

Patient sustained injury while playing with an iron rod about six years prior to presentation to the Clinic. Fluid discharge from the cheek was noted two weeks after the traumatic episode particularly on sighting food.

Maxillofacial examination revealed a 1 x 1 cm scar on the left cheek about 3 cm antero-superior to the angle of the mandible with a central fistulous opening discharging fluid on milking the parotid (Figure 1). There was no salivary flow from the Stenson's duct.

Based on location and clinical examination a diagnosis of posttraumatic parotid duct fistula was made. Haematologic and biochemical investigations were within normal limits. Patient was subsequently prepared for surgery.

Operative procedure

Under a naso-endotracheal intubation patient was draped after routine cleaning. The proximal and distal parts of the ducts were identified and cannulated with a size 10 feeding tube (Figure 2). Parotid gland was milked to confirm cannulation and continuity of proximal and distal parts of the duct. The fistulous area was de-epithelized and closed in 2 layers using vicryl 3/0 sutures (Figure 3).

*Corresponding Author E-mail: mfujijs@gmail.com

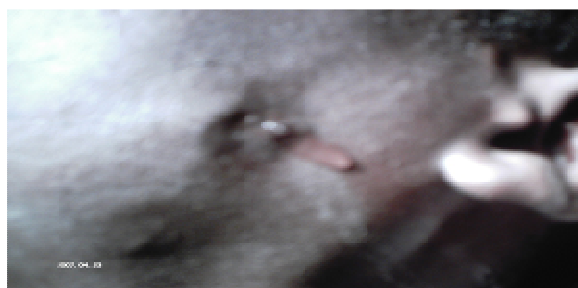


Figure 1: Parotid duct fistula with salivary flow on stimulation

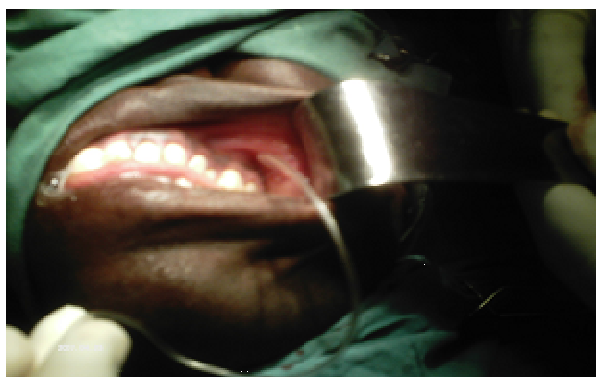

Figure 2. Indwelling nasogastric tube in the parotid duct

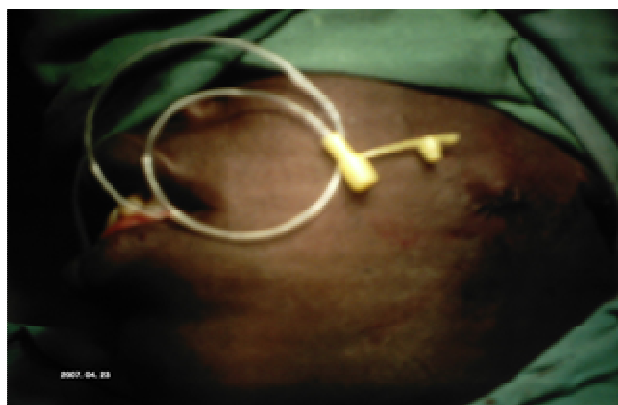

Figure 3. Indwelling nasogastric tube with fistula closure

Post-operatively patient was managed with clindamycin caps 150mg every eight hours for five days and metronidazole tabs 400mg every eight hours for five days. I.M. penatocine 30mg stat and tabs paracetamol two twelve hourly for three days. He was discharged 10 days post operatively with an in-dwelling nasogastric tube which was removed one month post-operatively following

satisfactorily healed site with no fluid discharge from the surgical site.

DISCUSSION

A thorough examination of facial lacerations particularly over the masseteric muscle region should include the parotid duct, if a fistula is not to be missed as parotid fistulae usually follow injury to that region. The most common cause of parotid duct fistula is trauma (Chadwick et al., 1979; Parekh et al., 1989). The case reported here resulted from a traumatic fall with laceration which was sutured. While digital sialography with fistulography demonstrates the precise anatomic location of a fistula (Gadodia et al., 2008; Parekh et al., 1989), no sialography or fistulography was done in this case, because the fistula was evident clinically, on sighting food, and while patient was eating by the drooling of saliva (Figure1) and was further confirmed by the milking of the left parotid gland.

With the use of sialography, Parakh et al. (1989) classified parotid injury into:

a. Glandular injury- type1: injury to the parenchyma or to minor ducts (G1), type 2: injury to a major intraparotid ducts (G2).

b. Ductal injury – type 1 (a): partial transection of the parotid duct [D1 (a)], type 1 (b): complete transection of parotid duct [D1 (b)], type 2(a): partial disruption of parotid gland-duct junction [D 2 (a)] and type 2(b): complete disruption of the parotid gland-junction [D 2 (b)].

Although, no sialography was done in our reported case, we believe this is of the type D 1(a) variety because there was no salivary flow intraorally through the Stenson's duct.

The management of parotid duct fistulae remains controversial. Depending on the anatomical location and the type of injury a wide choice of treatment (Arnaud et al., 2008; Heymans et al., 1999; Liang et al., 2004) (surgical and non-surgical) options exist. Surgical management include diversion of the remaining proximal duct into the oral cavity (Abramson et al., 1973; Doctor et al., 2007), primary anastomosis (Abramson et al.,1973), ligation of the proximal duct (Abramson et al.,1973), vein grafting of the duct (Ananthakrishnan and Parkash, 1982; Heymans et al., 1999; Liang et al., 2004), tympanic neurectomy(Chadwick et al., 1979) , and parotidectomy (Parekh et al, 1989). According to Ananthakrishnan and Parkash (1982), successful closure is obtained in only 50% of the patients with long standing fistulas.

Non surgical approach includes the administration of anti-sialogogues (Arnaud et al, 2008; Breuer et al, 2006; Ellis et al., 2004), non administration of food orally (Ananthakrishnan, Parkash, 1982) to depress parotid secretion, and radiation of the gland (Abramson,1973). A more current and non surgical approach is the injection of

Botulinum toxin A (Arnaud et al., 2008; Breuer et al., 2006) into the glands under sonography. Ellis et al (2004) found this very useful in the management of 33 patients with drooling from the salivary fistulae. However, these anti-sialogogues and botulinum toxin A are not readily available in our country.

CONCLUSION

Soft tissue injury of the face should raise a high index of suspicion of trauma to the parotid parenchyma and the duct. History of injury to the gland area, location of the fistula and nature of the discharge is also characteristic. We report the successful surgical management of a long-standing type D 1(a) parotid duct fistula using a nasogastric tube for stenting of the repair in a poor resource setting.

REFERENCES

- Abramson M (1973). Treatment of parotid duct injuries. *Laryngoscope* 83(11): 1764 – 1768.
- Ananthakrishnan N, Parkash S (1982). Parotid fistulas: a review. *Br. J. Surg.* 69(11): 641-643.
- Arnaud S, Batifol D, Goudot P, Yachouh J (2008). Non-surgical management of parotid gland and duct injuries: inters of botulinum toxin. *Ann. Chir. Plast. Esthet.* 53(1): 36-40.
- Breuer T, Ferrazzini A, Grossenbacher R (2006). Botulinum toxin A as a treatment of traumatic salivary gland fistulas. *Head Neck Oncol.* 54(5): 385-390.
- Chadwick SJ, Davis WE, Templer JW (1979). Parotid fistula: current management. *Southern Med. J.* 72(8): 922-926.
- Doctor VS, Rafii A, Enepekides DJ, Tollerfeson TT (2007). Intraoral transposition of traumatic parotid duct fistula. *Arch. Facial Plast. Surg.* 9(1): 44-47.
- Ellis M, Gottstein U, Rohrbach-Volland S, Arglebe C, Laskawi R (2004). Reduction of salivary flow with botulinum toxin: extended report of 33 patients with drooling, salivary fistulas, and sialadenitis. *Laryngoscope* 114(10): 1856-1860.
- Gadodia A, Seith A, Sharma R, Thakar A (2008). Congenital salivary fistula of accessory parotid gland: imaging findings. *J. Laryngol. Otol.* 122(3)
- Heymans O, Nelissen X, Medot M, Fissette J (1999). Microsurgical repair of stensen's duct using an interposition vein graft. *J. Reconstr. Microsurg.* 15(2): 105-107.
- Liang C, Jeng S, Yeh M, Liu Y, Kuo Y (2004). Reconstruction of traumatic stensen's duct using a vein graft as a conduit: two case report. *Annals Plast. Surg.* 52(1): 102-104.
- Parekh D, Glezeron G, Stewart M, Esver J, Lawson HH (1989). Posttraumatic parotid duct fistulae and sialoceles). A prospective study of conservative management of 51 cases. *Ann. Surg.* 209(1):105-111.