

Case Report

Spontaneous superior gluteal artery ruptures in patient with nephritic syndrome during Dalteparin treatment. A case report

Xiu-Hong Huang and Shu-E Zhao*

Education Department, the Third Hospital of Hebei Medical University, Shijiazhuang City, Hebei Province, 050051, China

Abstract

Superior gluteal artery (SGA) injury is a rare but well-known complication of blunt trauma usually associated with pelvic and acetabular fractures. Spontaneous SGA rupture has been rarely noted. We present the case of a 78 years old man with nephrotic syndrome who developed a spontaneous SGA rupture leading to a severe buttock hematoma while he was in treatment with dalteparin. Dalteparin was discontinued. The bleeding was stopped by selective angiographic embolization. Two units packed red blood cells transfusion was given. The patient medical status improved in one month. We reviewed the literature to identify the possible risk factors of bleeding. The results of this case, together with published literature demonstrate that even if the dalteparin is a safe medication, it should be used with caution in patients with impaired renal function, especially in advanced age. We wish to increase attention of the possibility of this kind of clinical problem and urge close monitoring for any unusual bleeding complications, particularly in the aged patient with renal insufficiency during dalteparin treatment.

Keywords: Superior gluteal artery, buttock hematoma, rupture, dalteparin.

INTRODUCTION

Superior gluteal artery (SGA) is the first branch of internal iliac artery. SGA injury is a rare but well-known complication of blunt trauma usually associated with pelvic and acetabular fractures (Zhang et al., 2010). Spontaneous SGA rupture has been rarely noted. It is more dangerous because if patient complains of buttock pain or buttock swelling is noted, arterial bleeding may not be initially considered as a likely cause. Delay in diagnosis in these cases can lead to significant morbidity and mortality. The present reported case is the first report of a patient developing severe hematoma due to spontaneous SGA rupture during Dalteparin treatment. We think that it is worthwhile to present such a case due to the scarcity of such complication and our intention is to

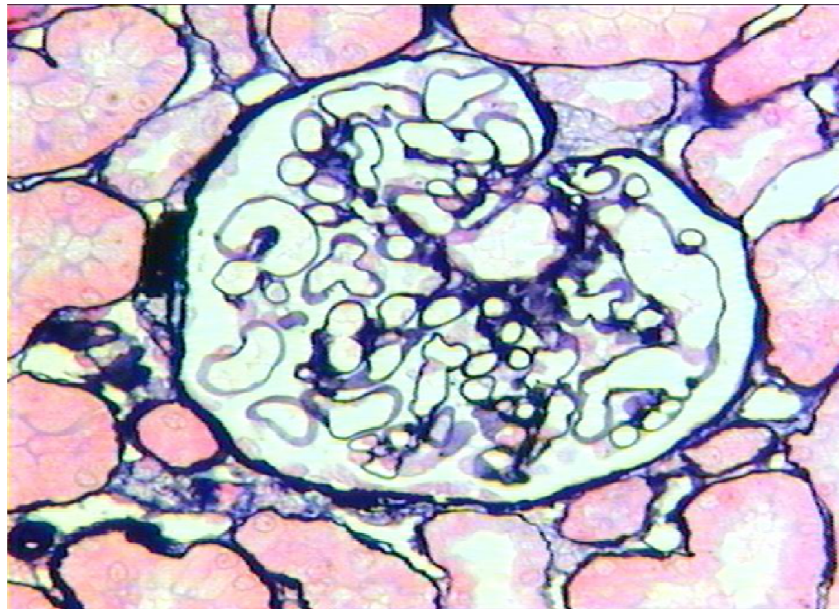
increase attention of the possibility of this kind of clinical problem.

Case report

A 78-year-old male was admitted to the hospital because of both lower limb oedema accompanied by headache, dizziness and decreasing exercise tolerance, lasting for about 10 days. At admission, vital signs was as follows: T 36.4°C, P 60/min, R 16/min, BP 168/90 mmHg. Both lower limbs were pitiful oedema. There was no history of hypertension, diabetes mellitus and CAD. The other clinical examination was uninformative. Major biological abnormalities were seen in routine laboratory tests: total protein 44.7 g/L, serum albumin 27.9 g/L, serum globuloprotein 16.8 g/L, serum creatinine 87 µmol/L, proteinuria 9.39 g/24 hours, HbsAg (+), HbeAb (+), HbcAb (+). Blood routine test showed: WBC $6.60 \times 10^9/L$, RBC $4.37 \times 10^{12}/L$, Hb 129 g/L.

*Corresponding Author E-mail: shuezhao@yahoo.com.cn;
Tel: 86(311)88603636

Figure 1. Minimal change disease on the renal biopsy, Masson Trichrome ($\times 400$).



The results of tests were suggestive for nephrotic syndrome. Benazepril was given at a dose of 5 mg every morning. Patient body weight and blood pressure was monitored after admission. Percutaneous renal biopsy was done 4 days later after admission in February 24, 2003. It showed minimal change disease with neither immunoglobulin nor complement deposits (Figure 1). Other etiologies of nephritic syndrome were eliminated. L-amlodipine 2.5 mg every night and oral furosemide 20 mg three times a day was given. Because of hepatitis B virus surface antigen, antinuclear antibodies and antineutrophil cytoplasm antibodies were positive, antiviral drug lamivudine at a dose of 100 mg every morning was given for two weeks before immunosuppressant was taken. Dalteparin was given at a dose of 5000 U two times a day to prevent deep vein thrombosis. After eight days therapy, plasma protein decreased to: total serum protein 42 g/l, serum albumin 19.7 g/l, creatinine increase to 201 $\mu\text{mol/l}$, Proteinuria was 13 g/24 hours. Pitting edema of lower extremity worsened. Plasma 150 ml was given intravenously.

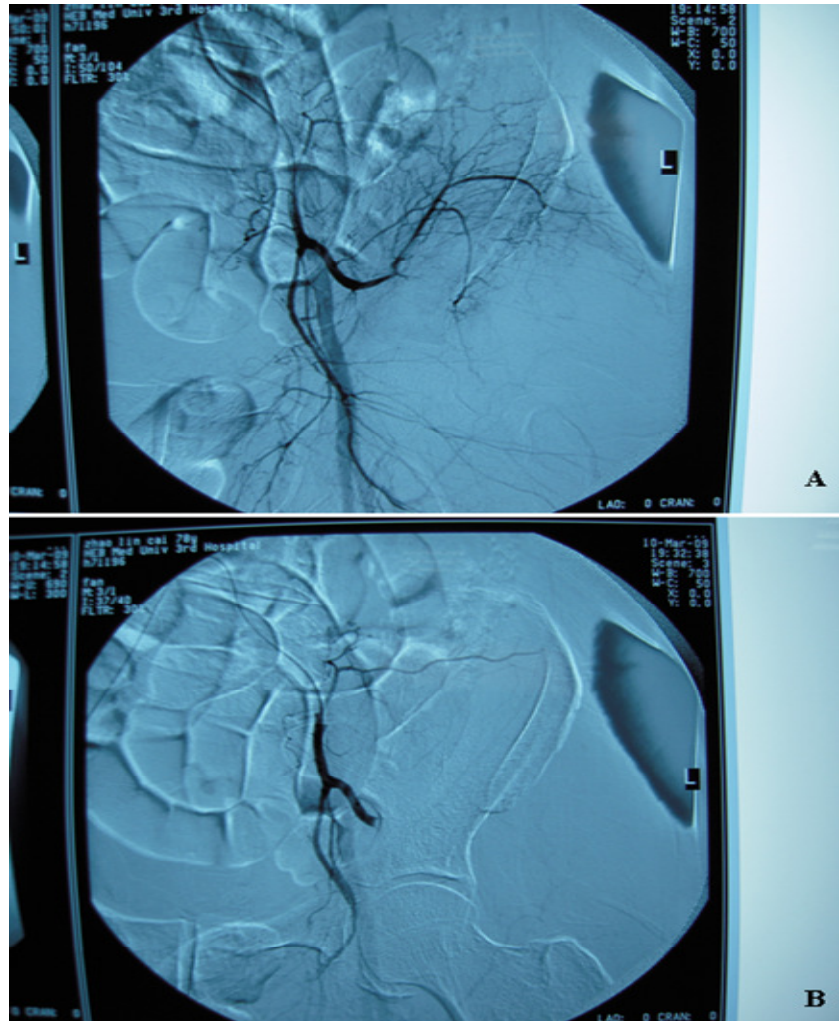
Severe left buttock pain was complaint by patient the next day morning. On examination: Patient looked pale. Left buttock was bulged, tenderness and hypertonia. Left leg felt numb and could not be elevated. P: 96, BP: 130/70 mmHg. His hemoglobin decreased from 135 g/l to 70.90 g/l. An urgent ultrasound revealed a large left buttock hematoma: 16.3 \times 7.6 cm. Heparin was discontinued. In

view of normal blood coagulant result, Syringe puncture was done after carefully disinfection and 400 ml blood was suctioned out. Pressure bandage was applied for hemostasis. Two units packed red blood cells transfusion was given. Left buttock pain was relieved temporarily. But four hours later, left buttock pain reoccurred and gradually exacerbated. Bedside ultrasound showed hematoma: 14.7 \times 7.3 cm. This was suggestive for active bleeding. Angiography was rapidly performed which showed extravasation of intravascular contrast material from a superior gluteal artery (Figure 2A). The bleeding was controlled with a selective angiographic embolization (Figure 2B). Because of severe pain and high tension of left buttock, syringe suction was given and 500 ml blood was suctioned out. Pain relieved. No further bleeding was noted. His medical status improved in one month and he was discharged with Proteinuria 1.9 g/24 hours.

DISCUSSION

SGA injury is a rare but well-known complication of blunt trauma usually associated with pelvic and acetabular fractures. This patient's SGA ruptured during rest status, not related to trauma, surgery or puncture. This case is the first report of a patient developing severe hematoma due to spontaneous SGA rupture while he was in treatment with Dalteparin. The reasons we considered are probably

Figure 2. SGA Angiography. **A** extravasation of intravascular contrast material from a superior gluteal artery, suggests active bleeding. **B** The bleeding was controlled with a selective angiographic embolisation



related to using of dalteparin, renal function impairment and old age.

Dalteparin is effective for prevention of venous thromboembolism, treatment of deep vein thrombosis (DVT), anticoagulation of patients undergoing hemodialysis or hemofiltration, and management of unstable angina (Dunn et al., 1996). Compared with unfractionated heparin (UFH), dalteparin and other low-molecular-weight heparins (LMWHs) offer a favorable pharmacokinetic profile, a predictable dose-response relationship, the possibility for administration in outpatient settings, and a decreased frequency of heparin-induced thrombocytopenia-important considerations for their widespread use (Smith and Gandhi 2001).

Dalteparin is derived from UFH through partial nitrous acid depolymerization. It inhibits mainly factor Xa,

whereas UFH inactivates a number of coagulation factors, including factor IIa (thrombin) and factor Xa. Dalteparin has an average molecular weight of 5600-6400 Daltons; it is excreted unchanged almost exclusively through the kidney (Howard and Dalteparin 1997).

Although bleeding risk has been shown to be lower with LMWH than with UFH in general (Schulman et al., 2008), several major bleeding complications have been reported in patients treated with LMWH in literature (Mrug et al., 2002; Chan-Tack 2003; Melde 2003; Ernits et al., 2005). Most cases are treated on enoxaparin. A few cases of major bleeding were reported during dalteparin therapy. Ganguli *et al* reported Spontaneous hemothorax following anticoagulation with dalteparin (Ganguli et al., 2009). Dalteparin induced retroperitoneal bleeding and Life-threatening hemorrhage on flank after dalteparin

therapy was reported by Carrascosa *et al* and Egger *et al* respectively (Carrascosa *et al.*, 2001; Egger *et al.*, 2005)

Bleeding risk is increased in patient with renal function impairment regardless of anticoagulant used (Sohal *et al.*, 2006). Chronic renal failure can increase the tendency of bleeding with various mechanisms such as decreased activity of platelet factor III, abnormalities of platelet aggregation and adhesiveness, high uraemia levels or direct injury to the vascular intimal layer. All these modifications can lead to a spontaneous rupture of arteries (Halak *et al.*, 2001). Vayá *et al* reported 9 cases of spontaneous hematoma during enoxaparin therapy. A certain degree of chronic renal insufficiency was present in 6 of them (Vayá *et al.*, 2003).

Dalteparin is eliminated primarily through the kidney; therefore, it may accumulate in patients with renal impairment. The literature includes reports of several patients with impaired renal function in whom the use of enoxaparin, another LMWH, led to increased antifactor Xa activity and bleeding (Bastani and Gonzalez 2002; Von and Magee 2003). Although case reports about pharmacokinetic data for dalteparin in humans with renal impairment are lacking, the half-life of dalteparin can be expected to increase with worsening renal function. A pharmacokinetic study in rabbits receiving nephrectomy showed that the plasma half-life of dalteparin was significantly longer than that of control rabbits (Palm and Mattsson 1987).

Age has been shown to be an independent risk factor for major bleeding (Schulman *et al.*, 2008). Age greater than 70 years has been shown to be associated with a clinically important increased risk of major bleeding due to age related changes in the pharmacodynamic and pharmacokinetic properties of heparin (Campbell *et al.*, 1996). Olderly patients, despite a normal serum creatinine value, can have a significantly reduced creatinine clearance (CrCl), that lead to an increase of anti-Xa activity and consequently to an increased risk of bleeding (Fortina *et al.*, 2007).

To our knowledge, this is the first case report of buttock hematoma induced by spontaneous superior gluteal artery rupture developed in the absence of any precipitating event while the patient was receiving dalteparin therapy. The results of this case, together with the published literature, demonstrated that even if the dalteparin is a safe medication, it should be used with caution in patients with impaired renal function, especially in advanced age. In these high risk patients monitoring LMWH with peak anti-Xa levels regularly is necessary. If there is no possibility of monitoring anti-Xa levels, the

using of LMWH should be avoided. We wish to alert nurses and urge close monitoring for any unusual bleeding complications, particularly in the aged patient with renal insufficiency.

REFERENCES

- Bastani B, Gonzalez E (2002). Prolonged anti-factor Xa level in a patient with moderate renal insufficiency receiving enoxaparin. *Am J Nephrol*;22(4):403-404.
- Campbell NR, Hull RD, Brant R, Hogan DB, Pineo GF, Raskob GE (1996). Aging and heparin related bleeding. *Arch Intern Med*;156(8):857-860.
- Carrascosa PM, del RMM, González RM (2001). Dalteparin-induced retroperitoneal bleeding. *Ann Pharmacother*;35(2): 261-262.
- Chan-Tack KM (2003). Fatal spontaneous retroperitoneal hematoma secondary to enoxaparin. *South Med J*;96(1):58- 60.
- Dunn CJ, Sorkin EM, Dalteparin S (1996). a review of its pharmacology and clinical use in the prevention and treatment of thromboembolic disorders. *Drugs*;52(2):276-305.
- Egger SS, Sawatzki MG, Drewe J, Krähenbühl S (2005). Life-threatening hemorrhage after dalteparin therapy in a patient with impaired renal function. *Pharmacotherapy*;25(6):881-885.
- Ernits M, Mohan PS, Fares LG, Hardy H (2005). A retroperitoneal bleed induced by enoxaparin therapy. *The Am Surg*;71(5):430-433.
- Fortina M, Carta S, Del Vecchio EO, Crainz E, Urgelli S, Ferrata P (2007). Retroperitoneal hematoma due to spontaneous lumbar artery rupture during fondaparinux treatment. Case report and review of the literature. *Acta biomed*;78(1):46-50.
- Ganguli A, Walker L, FitzGerald RJ, Pirmohamed M (2009). Spontaneous hemothorax following anticoagulation with low-molecular-weight heparin. *Ann of Pharmacother*;43(9):152831.
- Halak M, Kligman M, Loberman Z, Eyal E, Karmeli R (2001). Spontaneous Ruptured artery in a chronic renal failure patient. *Eur J Vasc Endovasc Surg*. June 21(6):569.
- Howard PA (1997). Dalteparin: a low-molecular-weight heparin. *Ann Pharmacother*;31(2):192-203.
- Melde SL (2003). Enoxaparin-induced retroperitoneal hematoma. *Ann Pharmacother*;37(6):822-824.
- Mrug M, Mishra PV, Lusane HC, Cunningham JM, Alpert MA (2002). Hemothorax and retroperitoneal hematoma after anticoagulation with enoxaparin. *South Med J*;95(8):936-938.
- Palm M, Mattsson C (1987). Pharmacokinetics of heparin and low molecular weight heparin fragment (Fragmin) in rabbits with impaired renal or metabolic clearance. *Thromb and Haemost*;58(3):932-935.
- Schulman S, Beyth RJ, Kearon C, Levine MN (2008). Hemorrhagic complications of anticoagulant and thrombolytic treatment: American college of chest physicians evidence-based clinical practice guideline. *Chest*;133(6 Suppl): 257S-298S.
- Smith BS, Gandhi PJ (2001). Pharmacokinetics and pharmacodynamics of low-molecular-weight heparins and glycoprotein IIb/IIIa receptor antagonists in renal failure. *J Thromb Thrombolysis*;11(1):39-48.
- Sohal AS, Gangji AS, Crowther MA, Treleaven D (2006). Uremic bleeding: pathophysiology and clinical risk factors. *Thromb Res*.118(3):417-422.
- Vayá A, Mira Y, Aznar J, Todolí J, Arguedas J, Solá E (2003). Enoxaparin-related fatal spontaneous retroperitoneal hematoma in the elderly. *Thromb Res*;110:69-71.
- Von Visger J, Magee C (2003). Low molecular weight heparins in renal failure. *J Nephrol*;16(6):914-916.
- Zhang Q, Chen W, Smith WR, Pan J, Liu H, Zhang Y (2010). Superior gluteal artery injury presenting as delayed onset shock. *Arch Orthop Trauma Surg*;130(2):251-256.