

Full Length Research Paper

Raised serum estrogen and progesterone concentrations in female rats treated with extract of *Alstonia boonei* (De wild)

Oze G.¹, Onyeze G.O.², Ojiako O.², Abanobi S.², Ozims S.³, Ohiri Alison⁴

¹Institute of Neuroscience and Biomedical Research, Faculty of Medicine, Imo State University, Owerri

²Department of Biochemistry, Federal University of Technology, Owerri

³Department of Public Health, Imo State University, Owerri

⁴Faculty of Medicine, Imo State University, Owerri

Accepted 15 June, 2012

Alstonia boonei (Ab) is a deciduous plant used in Nigeria for the treatment of various ailments. It is reputed in traditional medicine to have anti-malarial, antipyretic, analgesic, and anti-inflammatory properties. Many anti-malarial and antibiotic agents have been reported to have anti-fertility actions. For instance, the anti-fertility action of quinine and chloroquine has been documented. Studies have proven the anti-fertility effect of Ab in male rats. The effect of Ab on the reproductive parameters of female rats attracted our research attention. The concentration of female sex hormone may vary significantly depending on the menstrual phase, and this affects female reproductive function. The aim of this research is to investigate the effect of *Alstonia boonei* stem bark extract on the serum estrogen and progesterone concentrations in mature non-pregnant female rats. We adapted the method of Skibola et al., (2004), Forty rats, weighing 100-150g were randomly allocated to eight experimental groups of 5 rats each. Group 1 was given 0.5ml/kg normal saline and served as the control. Groups 2, 3, and 4 received 50, 100, and 200mg/kg of the extract daily for 2 weeks respectively. The doses were repeated for groups 5, 6, 7, and 8 for 4 weeks respectively. All drug administration was by oral intubation. At the end of the respective periods, the rats were sacrificed under chloroform anaesthesia. The serum concentrations of the hormones were determined using Eleesys auto analyzer (model 1010, Roche, Mannheim, Germany). The histology of the uterine cells was studied using the method adopted by John et al., (1990). The plant extract elevated the serum concentrations of estrogen and progesterone at higher doses and longer periods ($p > 0.05$). The serum hormonal increase by the 2nd and 4th weeks, and at 50mg/kg were not significant ($p < 0.05$). The results indicated that treatment with Ab stem bark extract on female rats increased the serum concentration of female sex hormones. This effect is more prominent in the group with higher dosage, and persisted with prolonged administration. We conclude that the extract has possible stimulant effect on female estrogen and progesterone. It may be useful for female contraception (knowing that sustained increase in blood progesterone and estrogen inhibits ovulation). Further, Ab extract should not be administered repeatedly or in high doses when fertility is desired.

Keywords: *Alstonia boonei* extract, estrogen, progesterone, female rats.

INTRODUCTION

Alstonia boonei is a deciduous plant that is native to the tropics and sub-tropical regions of the world (Katende,

1995). The crude extracts of *A. boonei* are extensively used in folkmedicine by a reasonable percentage of the population especially in developing nations to treat malaria, mental illness, inflammatory diseases and reproductive disorders. But there is dearth of organized scientific information about their beneficial or deleterious

*Corresponding Author E-mail: gabrieloze@yahoo.com

effects, as well as the measure of safety. In the light of the foregoing, this work attempts to provide some scientific information on some aspects of the biochemical parameters of the extract.

In females, plasma progesterone concentration remains relatively constant throughout the follicular phase of the menstrual cycle. The concentration then increases rapidly following ovulation and remains elevated for 4-6 days and decreases to the initial level 24 hours before the onset of menstruation. In pregnancy, placental progesterone production rises steadily to levels of 10 to 20 times those of the luteal phase peak. (Waugh and Grant, 2006) Progesterone measurements are thus performed to determine ovulation as well as to characterize luteal phase defects. Monitoring of progesterone therapy and early stage pregnancy evaluations are some of the uses of plasma progesterone determination (Carr et al. 1992).

Some drugs and chemicals have been studied and found to adversely affect the uterus and related structures. The thalidomide episode of the 1940s and 50s has remained a classic reference point for the eminent dangers of chemicals on the female reproductive system. The contagen which was the offending drug that caused the phocomelia was withdrawn from the market in the 1960s, but the bitter lesson of that experience underscores the vital importance of toxicity studies on possible drug candidates on the female reproductive organ. Kayode et al., (2007) reported the adverse effect of the methanolic extract of *Aspillia africana* leaf on the estrous cycle and uterine tissues of rats in which they showed that the extract caused reduction in uterine weight and prevented implantation of the fertilized ovum. Fukuda et al., (1984) reported the likely oxytocic effect of *Huntera umbellata* on isolated rat uterus. The effect was traced to the alkaloidal component of the plant extract. The studies on the chloroform extract of *Carica papaya* seed on the estrous cycle and fertility in female albino rats showed that the extract caused mild histological changes and significant reduction in serum estrogen (Raji et al., 2005a, 2005b). Cherian (2000), demonstrated that the extract of the latex of *C. papaya* caused cytological disruption of the isolated gravid and non-gravid uteri.

Studies on the possible mechanism for the anti-fertility effect of root extract of *Rumex stendellii* showed that the extract stimulated the uterine smooth muscle thereby preventing the implantation of the ovum. The extract also decreased the serum levels of estrogen and progesterone in the rats (Endalt et al., 2005). Furthermore, Vasudeva et al. (2007) also documented the anti implantation effect of *Hibiscus rosa-sinensis* root extract on uterine epithelium. Azadey et al. (2007) demonstrated the anti-fertility effects of *physalis alkekengi* alcoholic extract in female rats. The work further revealed that the extract reduced the number of implantation sites in the uterus and also caused a decrease in serum estrogen and progesterone levels.

Phytoestrogenic extracts may have pro-hormonal or anti-hormonal effects on mammalian system. The resultant effect is multifaceted ranging from histological and biometric changes, teratogenicity and abortifacience; as well as alteration in the implantation sites. The abnormal elaboration of these hormones is bound to have adverse effects on the organs. Furthermore, it is established that hormonal balance is essential for implantation and proper development of the product of conception (William, 1999; Guyton, 2003).

With the renewed efforts in the development of alternative antimalarial drugs due to the challenges posed by the chloroquine resistant strains of malaria parasites, the scientific evaluation of *A. boonei* stem bark extract, which is a common antimalaria agent in folkmedicine becomes necessary. In the absence of adequate information on the reproductive toxicity of *Alstonia boonei*, whose extract is globally employed in mental illness and malaria chemotherapy in local settings, the present work serves useful purpose to supply some of the information. Further, no literature was found with the histopathologic study on the reproductive organs of animals treated with *A. boonei*. This study will help to bridge the information gap especially in rats.

MATERIALS AND METHODS

Plant Materials

The stem bark of the plant was collected from Aboh Mbaize, Imo State, Nigeria; and was identified by a plant taxonomist, Dr S.C. Okeke, Department of Plant Science and Biotechnology, Imo State University, Owerri.

Extraction Procedure

The stem bark was cut into pieces, washed and dried in an oven (Accumax, India) at a temperature of 50°C. The stem bark was ground to fine powder using Thomas Contact Mill (Pye, Unicam, Cambridge, England). The powdered substance was weighed (1000g) using digital electronic scale (Scout, Ohaus, model SC 2020, a product of Ohaus Corporation, Pine Brook, N.J., USA). The powder was soaked in 10L of 70% ethanol using a stainless steel extractor, stirred and allowed to stand for 24hours. The extract was drained dropwise into amber coloured Winchester bottles from where it was concentrated under reduced pressure using rotatory evaporator (Laborato, 4000, China). The residue was recovered with aliquots of ethanol. The resulting solid extract was weighed, and it gave a yield of 30.55g (3.06%) of dry powder. Appropriate concentrations were made for the study.

Animals

Forty female Wister albino rats (100-150g), were used. They were obtained from the Animal House Unit of the College of Medicine, Imo State University, Owerri. The rats were housed in stainless steel cages under standard laboratory conditions, 12 hours light/dark cycle. They had unrestricted access to water and feed (Guinea Feeds Ltd, Ewu, Edo State, Nigeria). The animals were weighed before the start of the experiment and re-weighed before being sacrificed. The experiment was approved by the Faculty of Medicine Ethical Committee, and followed the "Guide for Care and Use of Laboratory Animals (National Research Council, 1966).

Experimental design

This followed the adaptation of the method of Skibola et al. (2004). Forty rats were randomly assigned to experimental groups of five rats each, and housed in separate cages with identification ear marks. Group 1 served as the control and received 0.5ml/kg normal saline (NS) for 2 weeks, in addition to feed and water. Groups 2, 3 and 4 received 50, 100 and 200mg/kg of the *Alstonia boonei* stem bark extract for 2 weeks, respectively. The rats in group 5 served as the next control and was given 0.5ml/kg NS for four weeks. Groups 6, 7 and 8 received 50, 100 and 200mg/kg of the extract for the same period. The extract was given by oral intubation in all cases.

Sample collection

The animals were fasted for 12 hours after the last extract administration, and sacrificed under chloroform anaesthesia. The blood was drawn by cardiac puncture for the hormonal assay. The uterus was dissected, cleansed with normal saline and transferred to 10% formaline for histological studies

Biochemical assay

The serum concentration of estrogen and progesterone were determined using Elecsys auto-analyzer (Model 1010, Roche, Mannheim, Germany)

Statistical analysis

Data collected were analyzed using statistical software package (SPSS, Version 15) at 95% confidence limit.

Histological analysis

The method of Drury and Wallington (1980) as modified by John et al., (1990) was adopted. The tissue was placed in 10% formaline for 5 days for proper fixation. It

was processed using automated Histokinetic Tissue Processor II (Miles, U.S.A). The serial sections were processed with Spencer's Cryostat and Hertz Rotary Microtome (Model 1010 – SMT – 011, England). The microscopic examination and analysis were done using Olympus stereomicroscope with digital photomicrographic camera (Leica, DM500, Lasez, Switzerland) attached to one of the eye-piece; and the image projected to a computer for analysis, editing and printing.

RESULTS

Biometric Findings

The three doses of the extract, 50, 100 and 200mg/kg retarded the weight of the female rats in 14days of treatment. The mean weight gain in the control was consistent over the period with a percentage gain of $85.6 \pm 3.5\%$. The weight gain depreciated in the test groups over the period by $40.2 \pm 5.1\%$, $22.7 \pm 3.1\%$ and $4.7 \pm 0.7\%$ for 50, 100, and 200mg/kg body weight respectively. This represents a significant ($p < 0.05$) growth retardation of the rats in the test groups.

The Ab had significant ($p < 0.05$) effects on serum estrogen concentration at 200mg/kg body weight for the 2 and 4 wks segments (Figure 1). The highest values were 60.6 and 84.6pg/ml respectively, against a control value of 43.2pg/ml. The increase was not significant ($p > 0.05$) at 50 and 100mg/kg for 2wks. But rose from a control value of 43.2pg/ml to 55.6pg/ml by the 4th wk. ($p < 0.05$) (Figure 1).

The administration of *A. boonei* stem bark extract had significant effect on the serum progesterone concentration. At two weeks after administration, the highest concentration of progesterone, 0.78ng/ml was recorded from the rats which received 200 mg/kg. This value was significantly different ($p < 0.05$) from the 0.43ng/ml recorded for rats in the control. There was no significant difference ($p > 0.05$) observed at 50 and 100mg/kg compared with the control (Figure 2).

At four weeks, the increase in the concentration of progesterone was significant (1.37ng/ml) at 200mg/kg but not at 50mg/kg (0.57ng/ml) compared with the control value of 0.45ng/ml. (Figure 2). The histological presentation shows that Ab has adverse effects on the uterine tissues (Figure 3 – 7).

DISCUSSION

The results showed that *Alstonia boonei* extract (Ab) may have adverse biochemical effects on female reproductive parameters in rats. *Alstonia boonei* extract dose dependently elevated the rat serum estrogen and progesterone concentrations (Figure 1 and 2) and

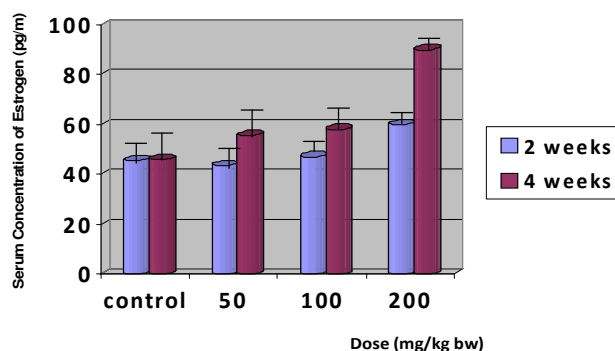


Figure 1. Serum Concentration of Estrogen against dose after administration of *A. boonei* stem bark extract.

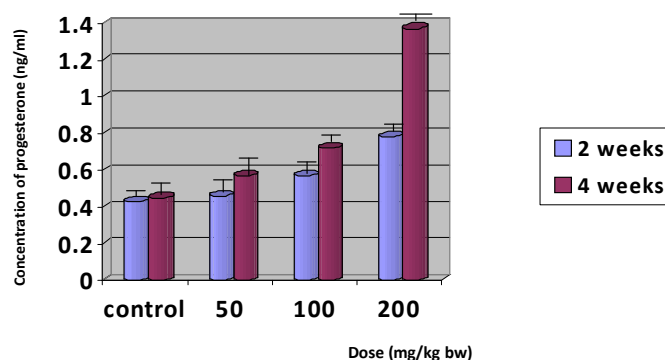


Figure 2. Serum Concentration of Progesterone against dose after administration of *A. boonei* stem bark extract.

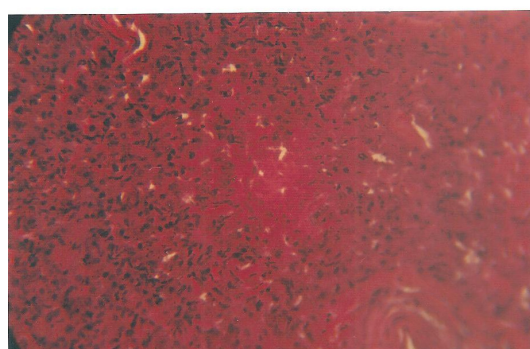


Figure 3. Photomicrograph of the uterus of control. It presents a normal structure of the uterus with endometrium having large epithelial cells with nuclei.

distorted the uterine tissue architecture which contained vacuolations and distortions of the uterine architecture, especially at 200mg/kg bw (Figure 4–7). The photomicrograph of the control showed the intact uterine cells (Figure 3).

There is a physiological plasma threshold concentration

of estrogen and progesterone that support fertilization, nidation and development of foetus (Vaugh and Grant, 2006). The alteration of this threshold leads to hormonal imbalance and adverse effects on the foetus (Pinaud et al., 1991; Ernan et al., 1996; Vasudervan and Sreekumaris, 2007). At physiologic concentration,

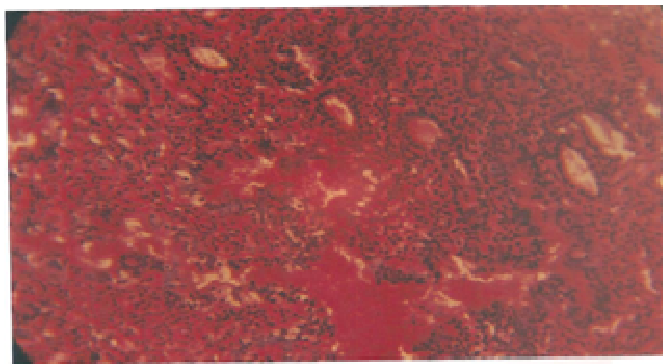


Figure 4. Photomicrograph of the uterus of rats treated with 50mg/kg of *Alstonia boonei* for 2 weeks. The endometrial glands are still intact, there are no significant histological changes

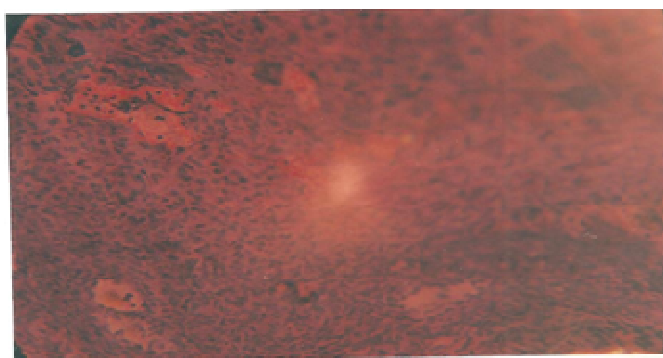


Figure 5. Photomicrograph of the uterus of rats treated with 200mg/kg of *Alstonia boonei* for 2 weeks. Irregular endometrial glands are present and the endometrial stroma are slightly disaggregated.

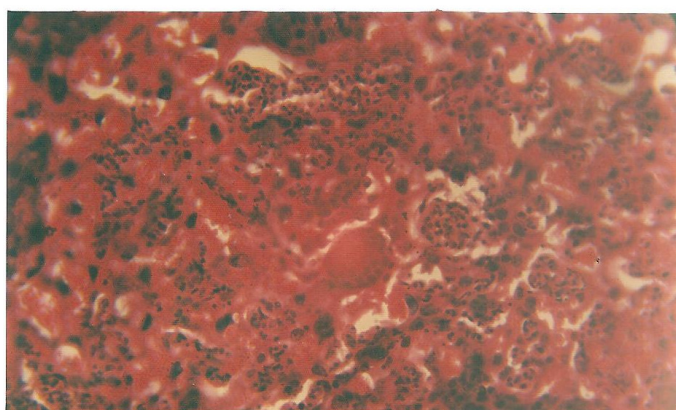


Figure 6. Photomicrograph of the uterus of rats treated with 50mg/kg of *Alstonia boonei* for four weeks. The tissue shows a cellular and pale stroma and the presence of pinkish deposits (haemorrhage). There are cellular infiltration of the glands, and distortion of the histology of the uterus

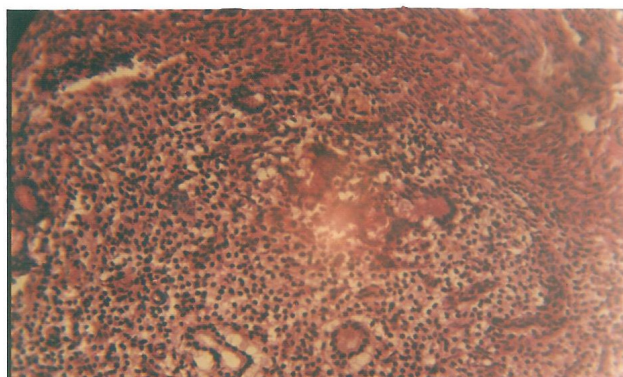


Figure 7. Photomicrograph of the uterus of rats treated with 200mg/kg of *Alstonia boonei* for four weeks shows proliferation of both glandular and tissue stroma. The stroma appeared to be pale and edematous. There is also the presence of pinkish deposits (haemorrhage).

progesterone induces synthesis of egg white proteins such as ovalbumin and ovumucoid (Gebrie et al., 2005; Pamir et al., 2006). Similarly, estrogen induces creatine kinase (Huang et al., 1987) but causes adverse proliferation of uterine cells, and embryonic defects at high serum concentration (Macco et al., 2008). Paoletti et al. (2001) and Tanriverdi et al. (2003) previously reported that high plasma estrogen concentration interferes with immune functions, and may have a role to play in the pathophysiology of autoimmune disease. Kayode et al., (2007) found out that elevated serum estrogen caused the distortions of the uterine cells in rats treated with *Aspillia africana* leaf extract. Gunin et al. (2005) reported the induction of morphogenetic alteration of uterine tissues as a result of high serum estrogen concentration, and to caution that the condition may predispose to cancer of the reproductive organs. They further suggested that estrogen may be associated with the acetylation of histone. They went further to show that the inhibitors of histone de-acetylase such as trichostan –A and sodium butyrate produced similar proliferation of mammary and endometrial cells as did high serum concentration of estrogen. This may serve as a possible explanation for the observed biochemical effects of cellular proliferation and distortions of uterine cells observed in this study. Furthermore, the anti-convulsant, sodium valproate, was found to antagonize histone deacetylase and caused teratogenicity and carcinogenicity in a similar way as trichostan-A. It is speculated that Ab may indirectly predispose to teratogenicity and carcinogenesis at high doses and prolonged usage because of its effects in increasing serum estrogen and progesterone concentrations.

CONCLUSION

From the foregoing, the ethanolic extract of *A. boonei*

may have deleterious biochemical effects on the reproductive parameters of female albino rats. This outcome may be a possible indication of the possible toxic effects on the human users of the plant extract. The study also showed that long term users of the extract may be exposed to the risk of carcinogenesis, teratogenesis and the form of cytotoxicity.

REFERENCES

- Azadey M, Maryam P, Mozafar K, Ghorbani R (2007). Anti-fertility effects of *Physalis alkekengi* alcoholic extract in female rats. *Iranian J. Reprod. Med.*, 5 (1): 13-16.
- Carr BR (1992). Disorders of the ovary and female reproductive tract. In: *Williams Textbook of Endocrinol.* W.B. Saunders, Philadelphia 733-798.
- Cherian T (2000). Effect of papaya latex extract on gravid and non-gravid rat uterus preparations in-vitro. *Ethnopharmacol.* 70; 205-212.
- Enan E, Larley B, Steward D, Oversheit J, Vandervoort LA (1996). 2,3,7,8 – tetrachlorodibenzo-p-dioxin (TCDD) modulates function of human Inteinizing granulocyte cells via CAMP signaling early reduction or g/c transporting activity. *Repr. Toxicol.*, 10:191-198 (medline).
- Endalk G, Eyasu M, Legesse Z, Asfaw E (2005). The possible mechanisms for the Anti-fertility action of root extract of *Rumex steudelii*. *J. Afri. Health Sci.*, 5 (2): 119-125.
- Fukuda M, Yamaouchi K, Nakano Y (1984). Hypothalamic laterality in regulating gonadotropic functions: unilateral hypothalamic and compensatory ovarian hypertrophy. *Neurosci. Lett.* 51:365-70.
- Gebrie E, Makonnen E, Zeri Hum L, Debella A (2005). The possible mech for the anti-fertility action of root extract of *Rummex stendelii*. *Afri. Health Sci.*, 5 (2): 119-125.
- Gunin GA, Kapitova IN, Sustonova NV (2005) effect of histone deacetylase inhibitors on estradiol-induced proliferates and hyperplasia formation in the mouse. *J. Endorcri.* 185:539-549.
- Guyton AC (2003). Female physiol. before pregnancy and the female hormones in: *Textbook of med. physiol.* 9th ed. W.B. Saunders company, Tokyo, 1017-1046.
- Huang H, Kissane J, Hawrylewicz J (1987). Restoration of sexual function and fertility by fetal hypothalamic transplant in impotent aged male rats. *Neurobiol. of Aging* 8(5): 465-472.
- John DM, Alan S, David RT (1990) *Standard Haematoxyline and Eiosin staining for Paraffin Sections. Theory and Pract. of Histol. Tech.* Churchill Livingston, 3rd Ed., Lon. pp 122.

- Katenda AB (1995). Musoga tree (*Alstonia boonei*) in: useful trees and shrubs of Uganda. Identification, propagation and management for agricultural and pastoral communities. Regional soil conservation unit, Swedish Int. Dev. Authority. 164-170.
- Kayode O, Uche O, Grills B, Tolulope D (2007). Toxic effect of methanolic extract of *Aspilia Africana* leaf on estrous cycle uterine tissue of wistar rats. *Int. J. Morphol.* 25(3): 609-614.
- Maccio A, Madedda C, Sana E, Panzone F, Volpe A, Mantovai G (2008). Evidence that Human serum with High level of estrogen interferes with immune system both by decreasing CD₂₅ expression on T-cell and by interleukin-2 availability. *Sci.*, 15(2): 962-969.
- National Research Council (NRC) (1966). Guide for the Care and Use of Laboratory Animals. Institute of Laboratory Anim. Res. National Acad. Press, Washington DC.
- Pamir E, Ali D, Ismail C, Sanli E, Ali K, Mustapha T (2006). The effect of high dose progesterone on neural tube development in early chick embryos. *Neuroendocrinol. India.* 54 (2): 178-181.
- Paoletti AM, Floris S, Mannias M, Orru M, Crippa D, Orland R, Del Meli B (2001). Evidence that cyproteron acetate improves suppressed psycho. symptoms and enhance activity of dopamine system in post menopausal lymphocytes. *J. Clin. Endocri. And Metabolism.* 186:608-612.
- Pinaud MA, Roser LF, Pybdal N (1991). Gonadotropin releasing hormone (GnRH) Induced Luteinizing hormone (LH) secretion from performed human pituitaries. *Domest. Anim. Endocri.* 8:353-368 (medline).
- Raji SM, Bindu M (2005a): Illustrated med. Biochem. 1 st ed. Brjbasi press Lt. New Delhi. pp 152-153,172-176.
- Raji YI, Salmon TM, Akinsomoye OS (2005b). Reproductive functions in male rats treated with methanolic extract of *Alstonia boonei* stem bark. *Afri. J. Biomed. Res.*, 8 (2):105-111.
- Skibola CF, Curry JD, Veori CV, Contis A, Sonith MT (2004). Brown Kelp Modulates Endocrine hormones in female Sprague – Dawley rats and in Human Inteinized granulose cells. *Biomed.* 4:10.
- Tanriverd F, Silveira L, MacColl G, Bouloux P (2003). The hypothalamic-pituitary-gonadal axis: Immune functions and autoimmunity. *J. Endocri.* 176:293-304.
- Vasudeva N, Neeru V, Sharma SK (2007). Post-coital antifertility activity of hibiscus rosa-sinensis Linn roots. *Comparative and alternative medicine* 5(i): 91-94.
- Vasudevan D, Sreekumaris M (2007). Textbook of Biochemistry for medical students. 5th ed. Jaypee. New Delhi. pp 516.
- Waugh A, Grant A (2006). Anatomy and Physiology in health and illness; 10th ed. Allison Churchill Livingstone. Elsevier. Toronto. pp 447-448.
- Williams PL, Banaister LH, Berry MM, Collin P, Dyson M, Dussek JE, Ferguson MW (1999). Gray's anatomy in: Reproductive system. 38th ed. Churchill Livingstone. 18. 73-74.