

*Full Length Research Paper*

# Modulatory effect of sweet almond extract on serum lipids, lipid peroxidation and histology of pancreas in alloxan-induced diabetic rats

<sup>1</sup>Etim O.E, <sup>2</sup>Bassey E.I\*, <sup>3</sup>Ita, S.O, <sup>4</sup>Udonkang, I.C, <sup>5</sup> Etim, I. E and <sup>6</sup>Jackson, I.L

<sup>1</sup>Department of Biochemistry, <sup>2</sup>Department of Anatomy, <sup>3</sup>Department of Physiology Faculty of Basic Medical Sciences, University of Uyo.

<sup>4</sup>Department of Pharmaceutics and pharmaceutical technology, <sup>5</sup>Department of Pharmaceutical and medicinal Chemistry, <sup>6</sup>Department of Clinical Pharmacy and Biopharmacy, Faculty of Pharmacy, University of Uyo.

Accepted 8 August, 2011

**The modulatory effects of sweet almond extract on lipid peroxidation, serum lipids, and histology of pancreas in alloxan-induced diabetic wistar rats was studied. Serum lipids and lipid peroxidation levels were determined using appropriate chemical techniques. Total cholesterol (TC) and low density lipoprotein (LDL) activities significantly increased in the diabetic groups of animals treated with 300mg/kg, 400mg/kg and 500mg/kg body weight of sweet almond extract in a dose dependent fashion while high density lipoprotein (HDL) showed a significant ( $P < 0.05$ ) decrease. Triglyceride (TG), very low density lipoprotein (V L D L) and lipid peroxidation (LP) decreased significantly. Modulatory activity of sweet almond on the histology of the pancreas of diabetic wistar rats treated with 300 mg/kg and 400mg/kg body weight of sweet almond extract was significant and pronounced compared to the untreated diabetic group of animals. There was a corresponding regeneration of acinar cells and the islet cells of Langerhans with prominent nuclei, an indication of restored function. The anti-lipid peroxidation and serum lipid modulatory activities of sweet almond extract shows ability to protect, reduce pancreatic damage and risk of diabetic complication.**

**Key words:** Sweet almond, lipid peroxidation, serum lipids, histology and diabetes.

## INTRODUCTION

Substances derived from plants remain the basis for a large proportion of commercial medications used in the treatment of various ailments. Towards these, research is carried out on plant materials for their potential medicinal value (Friedlie, 2004).

*Prunus dulcis* (sweet almond) is a fruit whose phytochemical constituents are potent medicine. It offers a broad array of healthful benefits. Monounsaturated fats, a constituent of this fruit is a type of health promoting fats associated with reduced risk of heart disease (Jenkins et al., 2005). The presence of vitamin E in sweet almond fruit may be another advantage of using this fruit since vitamin E is an important antioxidant which mops up free radicals produced in the body. Functional antioxidants

agents of plants origin play significant roles in ameliorating tissue toxicity in both human and animals. Several authors have reported on the effects of herbal extract on serum lipids activities (Bendich, 1989). Herbal extracts have also been reported to modulate the activities of serum lipid peroxidation.

The pancreas is a storage depot for digestive enzymes and hormones. One of such hormone is insulin which promotes the uptake of glucose by most cells, particularly those of the liver, skeletal muscle and adipose tissue, thus lowering plasma glucose concentration. Injury to the pancreas leads to impaired functions. The complications of diabetes mellitus are morphological consequences of many altered metabolic pathways which may be associated with increased free radical and serum lipid activities (Sheetz et al., 2002). This study therefore explores the modulatory effect of sweet almond fruit extract on some indices of lipid serum, lipid peroxidation

---

\*Corresponding author email; [godsgloryproject1@yahoo.com](mailto:godsgloryproject1@yahoo.com)

and corresponding morphological changes in the pancreas of diabetic animals.

## MATERIALS AND METHODS

### Collection and Extraction of Plant Materials

Sweet Almond were obtained from University of Uyo and Forestial Camp at Ikot Abasi in Akwa Ibom State. The fruits were washed, sliced and dried in an oven for one-day until the fruits were free of moisture. It was homogenized into powdered form and sieve to a fine mixture, it was further macerated with 200ml of absolute ethanol according to the method of Ugochukwu (Ugochukwu et al., 2003), in a beaker and allowed to stand for few minutes before filtering. The filtrate was lypholysed to dryness in a steam bath for some days leaving behind a jelly paste with a honey-like odour and the extract preserved in the refrigerator ready for analysis.

### Animal Treatment

Thirty mature albino rats of both sexes weighing between 150g-200g were used in this work. The animals were collected from the University of Uyo animal house. All the animals were carefully assessed and confirmed to be free of any pathological condition following the period of acclimatization to the experimental conditions, which lasted for seven days. They were fed with rat pellets and water was given ad libitum. The animals were housed in cages, College of Health Sciences in the University of Uyo animal house with adequate ventilation.

The animals were randomly selected into 5-groups of 6 animals each, having one control and 4 experimental groups. In the experimental groups (diabetes was induced by starving the animals for one day and their blood glucose level tested) after which diabetes was induced by a single intraperitoneal administration of 150 mg/kg body weight of alloxan, dissolved in distilled water.

### Experimental Design

Group 1 animals were induced with alloxan (diabetic) and given normal feed and tap water. Group 2 and 3 (diabetic) were treated with 300mg/kg and 400mg/kg body weight of ethanol extract of sweet almond respectively. Group 4 were treated with 500mg/kg body weight of ethanol extract of sweet almond after being induced with alloxan. Group 5 animals served as the control and received normal feed and tap water only. The treatment for control and the experimental animals lasted for 14-days.

### Animal Sacrifice and Preparation of Samples For Analysis

The blood glucose of the animals was tested again after the last day of administration. All the animals were anaesthetized using chloroform, 24 hours after the last administration of the extract. Blood samples were obtained by cardiac puncture into sterile plain tubes. Serum samples were extracted from the clotted blood into sterile plain tubes after centrifugation using an MSE model (England) bench centrifuge at 3000g for 10 minutes. The separated serum was stored in the refrigerator for analysis. All Biochemical analysis were carried out within 24 hours of sample collection. The liver was removed for assessment of lipid peroxidation. The pancreas were surgically removed immediately and suspended in 10% formol saline in specimen bottles for routine histological studies using Haematoxylin and Eosin staining technique (Drury and Wallington, 1976).

### Statistical Analysis

Statistical analysis of all the results were presented as mean  $\pm$  SD and students t-test was employed to assess statistical significance, values of  $P < 0.05$ ,  $P < 0.01$  and  $P < 0.001$  were considered to be significant.

### Determination of HDL- Cholesterol

HDL-cholesterol was determined using kits from RANDOX according to the method of Lapes-Virella et al., (1992).

### Determination of Triglycerides

Triglycerides was determined using triglyceride-GPO reagent set from TECO DIAGNOSTICS, according to the methods of (Fossat, 1982; McGowan et al., 1983).

### Determination of Total Cholesterol

Total cholesterol was determined using cholesterol reagent set from Teco Diagnostics according to the method of Allain et al., (1974).

### Determination of VLDL- Cholesterol

The very low density lipoprotein was obtained from the result of measured triglyceride divided by five.

$$\text{VLDL} = \text{TG}/5 \text{ (mmol/L)}$$

**Table 1:** The Mean Value of Serum Lipid Profile of Rats Treated With Different Doses of Ethanol Extract of Sweet Almond After 14 Days

GROUPS	TOTAL CHOLEST EROL (Mmol/L)	TRIGLYCERIDE (Mmol/L)	HIGH DENSITY LIPOPROTEIN HDL (Mmol/L)	LOW DENSITY LIPOPROTEIN LDL (Mmol/L)	VERY LOW DENSITY LIPOPROTEIN (Mmol/L)	LIPID PEROXIDATION (Mmol/L)
Diabetic control (DC)	4.84±0.06	2.18±0.02	0.99±0.06	4.28±0.09	0.44±0.00	0.08±0.01
Diabetic Treated (DT <sub>1</sub> , 300mg/kg)	4.91±0.25	2.10±0.04	0.99±0.04	4.34±0.04	0.42±0.01	0.07±0.01
Diabetic Treated DT <sub>2</sub> , 400mg/kg	4.84±0.85	2.07±0.06	0.88±0.02	4.37±0.15	0.41±0.01	0.07±0.01
Diabetic Treated DT <sub>3</sub> , 500mg/kg	4.95±0.25	2.09±0.03	0.98±0.04	4.38±0.08	0.42±0.01	0.08±0.01
Non-Diabetic control	5.04±0.27	2.18±0.04	1.07±0.1	4.46±0.1	0.43±0.1	0.06±0.01

**Table 2.** The mean value of serum lipid profile of rats treated with different doses of ethanol extract of *Prunus dulcis* (Sweet almond) after 14 days.

Groups	Total Cholesterol (mmol/L)	Triglyceride (mmol/L)	HDL (mmol/L)	LDL (mmol/L)	VLDL (mmol/L)	Lipid peroxidation (mmol/L)
Diabetic Control (DC)	4.84±0.06	2.18±0.02	0.99±0.06	4.28±0.09	0.44±0.00	0.08±0.01
Diabetic Treated(DT1; 300mg/kg)	4.91±0.25 <sup>a</sup>	2.10±0.04 <sup>a</sup>	0.99±0.04	4.34±0.04 <sup>a</sup>	0.42±0.001 <sup>g</sup>	0.07±0.00 <sup>g</sup>
Diabetic Treated (DT2; 400mg/kg)	4.84±0.85	2.07±0.06 <sup>a,b</sup>	0.88±0.02 <sup>a,b</sup>	4.37±0.15	0.41±0.01 <sup>g</sup>	0.07±0.01 <sup>g</sup>
Diabetic Treated (DT3; 500mg/kg)	4.95±0.25 <sup>a,b</sup>	2.09±0.03 <sup>c,e,f</sup>	0.98±0.04 <sup>c</sup>	4.38±0.08 <sup>a</sup>	0.42±0.01 <sup>g</sup>	0.08±0.01
Non-Diabetic Control (NDC)	5.04±0.27 <sup>a,b,d</sup>	2.18±0.04 <sup>c,d,e</sup>	1.07±0.1 <sup>a,b,c,d</sup>	4.46±0.1 <sup>a,d</sup>	0.43±0.1 <sup>a</sup>	0.06±0.01 <sup>g,h,i,j</sup>

**LEGEND**

a = significant different from DC (p<0.05) ; b = significant different from DT1 (p<0.05); c = significant different from DT2 (p<0.05); d = significant different from DT3 (p<0.05) ; e = significant different from DC (p<0.01); f = significant different from DT1 (p<0.01); g = significant different from DC (p<0.001) ; h = significant different from DT1 (p<0.001); i = significant different from DT2 (p<0.001) j = significant different from DT3 (p<0.001)

**Determination of LDL- Cholesterol**

The low density lipoprotein was estimated from the result obtained from measured total cholesterol, HDL and the calculated VLDL.

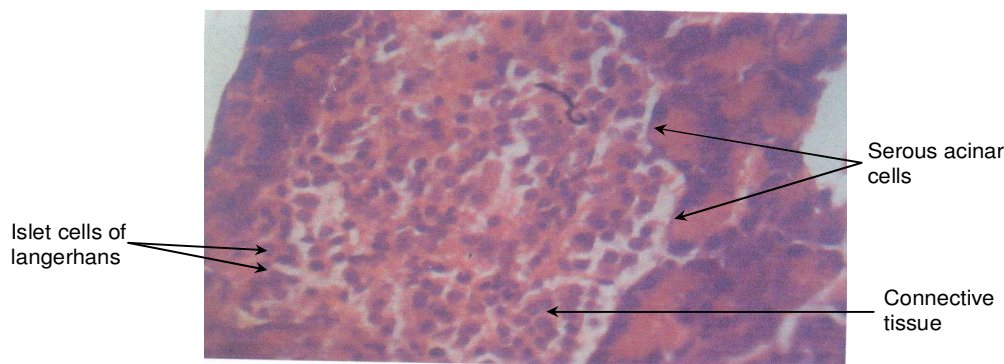
$$\text{LDL} = \text{T. Chol.} - \text{HDL} + \text{VLDL}$$

LDL is measured in mmol/L

**RESULTS**

The effects of sweet almond extract on serum lipids, lipid peroxidation and histology of pancreas in alloxan induced

diabetic rats are presented in **table 1**. Total cholesterol level in diabetic treated groups 1 and 3 increased significantly ( $P < 0.05$ ), compared to diabetic untreated (control) and diabetic treated group 2. Triglyceride level decreased significantly ( $P < 0.01$ ) in diabetic treated group 1, diabetic treated group 3 and ( $P < 0.05$ ) in diabetic treated group 2. It was observed that triglyceride level in diabetic treated group 2 and diabetic treated group 3 were significantly lower than diabetic treated group 1 ( $P < 0.01$ ) respectively. There was a significant decrease ( $P < 0.05$ ) in HDL level in diabetic treated groups 2 and 3 than diabetic untreated group and diabetic treated group 1.



**Figure 1.** Control group (Normal feed and tap water)

The result showed LDL values that was marginally higher in diabetic treated group 2 but significantly ( $P < 0.01$ ) higher in diabetic treated groups 1 and 3. There was significant ( $P < 0.01$ ) decrease in VLDL values in the diabetic treated groups compared to the untreated diabetic group. Lipid peroxidation values in the diabetic treated groups were significantly reduced ( $P < 0.01$ ) when compared with that of the untreated diabetic group.

Diabetic groups treated with 300mg/kg and 400mg/kg of ethanol extract of sweet almond showed a significant improvement morphologically when compared to the untreated diabetic group and diabetic group treated with 500mg/kg of ethanol extract of sweet almond.

The Histopathological state of the pancreas of the diabetic rats improved greatly with a gradual increase from 300mg/kg to 400mg/kg body weight of sweet Almond extract. In these histological sections the acinar cells appeared hyperplastic almost occluding the centro-acinar region, vacuolations were reduced and the islets cells of langerhans appeared regenerated with prominent nuclei compared to the diabetic untreated (control) sections where the acinar cells, the islets of langerhans and their nuclei appeared degenerated with large vacuolations within the entire section, and the pancreas of the diabetic rats were significantly smaller compared to that of the treated experimental animals.

It was observed that the histological sections of the diabetic groups that were treated with 500mg/kg body weight of ethanol extract of sweet almond appeared degenerated, with large sized vacuolations in the entire section. The acinar cell nuclei and islet cells were degenerated but the centro acinar regions were preserved. This is an indication of toxicity of sweet a almond at higher doses.

The pancreas of the control group (plate 1) reveals two areas:

1. The larger exocrine area made up of acinar cells that secretes pancreatic enzymes and alkaline bicarbonate.
2. The small endocrine area made up of islets cells of langerhans, they secrete the hormones, glucagons, insulin and somatostatin. For the test group Plate 3 which was treated with 300mg/kg of ethanol extract of *Prunus*

*dulcis* showed a significant improvement when compared to the diabetic group. There was no significant difference in test group Plate 5, but test group Plate 4 showed significant improvement when treated with 400mg/kg ethanol extract of *Prunus dulcis* when compared with the diabetic control Plate 2.

**Plate 1:** The acinar cells are columnar shaped and form the serous acinar which drains into the centroacinar region (light staining). Scattered within the acinar cells are large mass of cells called the islet cells of langerhans. They are separated from the acinar cells by a connective tissue capsule. In general the tissue appeared normal.

**Plate 2:** In this section, there is no clear distinction between the acinar cells and the islets of langerhans, islet cells are clustered together. Their nuclei appear to have degenerated. There are large vacuolations seen within the entire section. The centroacinar region appear to have been preserved.

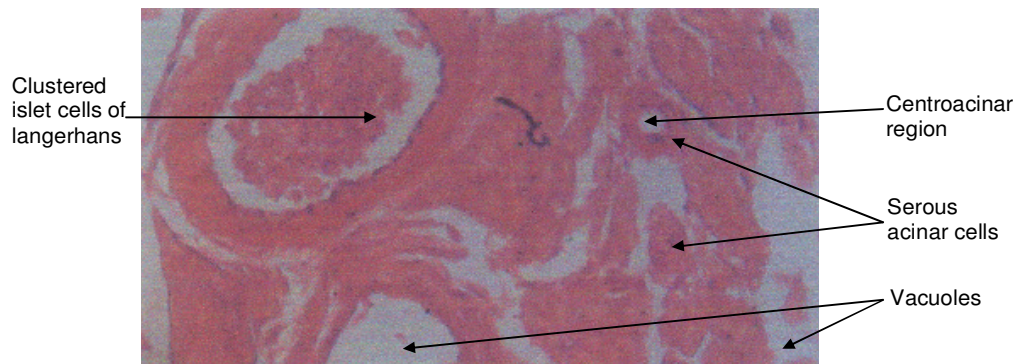
**Plate 3:** In this section, the acinar cells appear hyperplastic with numerous large-size nuclei. The centroacinar region appear to have been preserved in parts of the section. The islet cells appear atrophied with nuclei that appear degenerated. There are vacuolations throughout the section. Besides these, there are no other obvious pathology.

**Plate 4:** In this section the acinar cells appear hyperplastic, some almost occluding the centroacinar region. There are slight vacuolations throughout the section. The Islet cells appear regenerated with prominent nuclei. Besides these, there are no other obvious pathology.

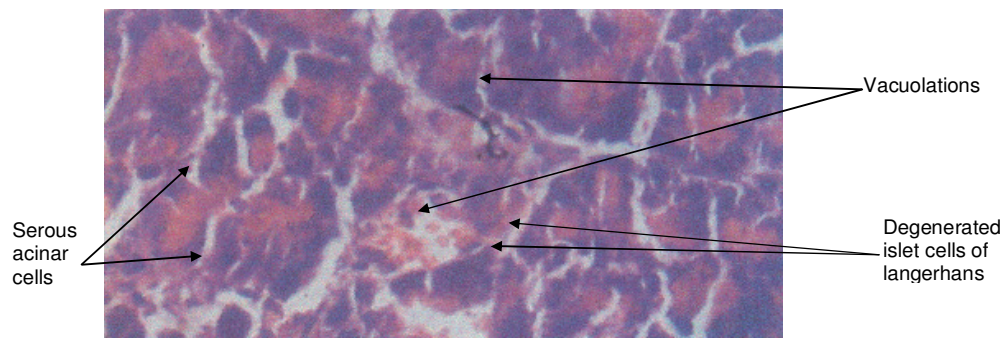
**Plate 5:** In this section, the acinar cells nuclei appear degenerated but the centroacinar regions appear preserved. There are large-sized vacuolations in the entire section. The islet cells cannot be seen in this

## DISCUSSION

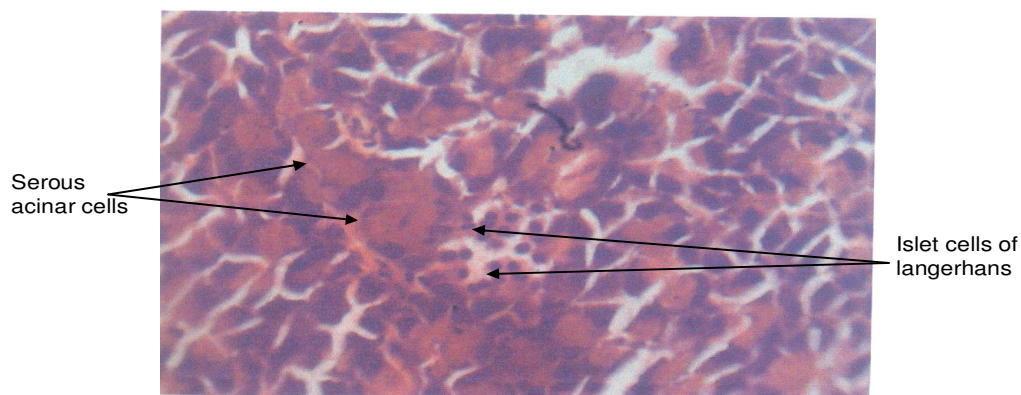
Alloxan monohydrate, a beta cytotoxin induces diabetes in a wide variety of animal species by damaging the section



**Figure 2.** Diabetic control group (Induced with alloxan and given normal feed and tap water), without extract.



**Figure 3.** Test group: (Administered 300mg/kg body weight of ethanol extract of *Prunus dulcis*).



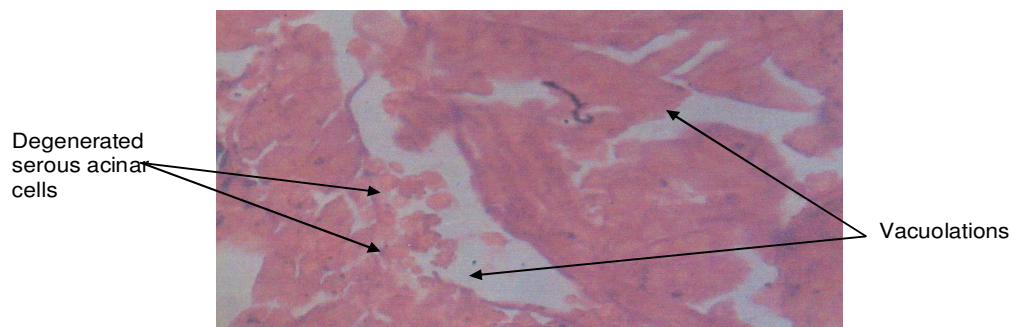
**Figure 4.** Test group, (Administered 400mg/kg body weight of ethanol extract of *Prunus dulcis*)

insulin pancreatic  $\beta$ -cells resulting in decrease in endogenous insulin release which lead to decrease glucose utilization by the tissues and a resultant diabetic (hyperglycemia) condition. An abnormality in glucose metabolism influences lipid metabolism as reported by (Oberley, 1988). Clinical knowledge of the level of serum lipids in an important biochemical tool in the toxicity or

beneficial effects of foreign compounds.

Serum lipids and lipid peroxidation are predominantly resident in body tissue. The physiological and pathological state of body tissues is highly associated with metabolism, level of serum lipids and lipid peroxidation. In situation where there is high activity of these lipids in body tissues due to oxidative damage, associated with





**Figure 5.** Test group: (Administered 500mg/kg body weight of ethanol extract of *Prunus dulcis*)

lipid metabolism, the administration of an antioxidant such as sweet almond extract may ameliorate tissue dysfunction since antioxidant are known to improve tissue integrity (Akhar et al., 1984).

In this study, it was observed that administration of sweet almond extract to alloxan induced diabetic rats resulted in a decrease in the serum levels of triglyceride, very low lipid density lipoprotein and lipid peroxidation at the dose level of 300mg/kg, 400mg/kg and 500mg/kg body weight of sweet almond extract. This indicates that triglyceride is elevated in diabetic patients because of destruction of the acinar cells in the pancreas responsible for the secretion of pancreatic lipase essential for lipid digestion. This results in accumulation of serum lipids. The level of very low-density lipoprotein was also elevated in diabetic condition because triglycerides are the major lipids in very low density lipoprotein. At the dose level of 300mg/kg and 400mg/kg body wt of sweet almond extract, there was a significant decrease in serum activity of triglyceride and very low lipid density lipoprotein though these doses corresponds with the stages where there was regeneration of the acinar cells.

However, total cholesterol, and low density lipoprotein showed a significant ( $P < 0.05$ ) increase at 300mg/kg to 500mg/kg wt of sweet almond extract compared to control. This study shows that insulin increase the number of low density lipoprotein receptors, so chronic insulin deficiency may be associated with a diminished level of low density lipoprotein receptor causing an increase in low density lipoprotein cholesterol value in diabetes mellitus (Saltiel, 2001).

The result showed a significant ( $P < 0.05$ ) reduction in HDL level in diabetic treated groups 2 and 3 than diabetic untreated (control) and diabetic treated 1. This may be due to selective sensitivity activity of serum lipids in physiological changes.

However, the highly significant decrease in the activity of triglyceride, VLDL and lipid peroxidation may be due to the presence of certain antioxidant vitamins, minerals and carotenoids in the sweet almond extract that are known to protect against oxidative stress in the tissue of human and animals. The mechanisms of growth promotion by

the extract may be related to enhance cellular anabolic processes in which carbohydrates, lipids and proteins are metabolized and stored in tissues, since high level of triglyceride leads to hyperglycemia which induce atherosclerosis or coronary heart disease. Sweet almond needs to be consumed to lower the effect (Piper, 1996).

The reduction of lipids by the extract allows for cellular repair and regeneration of beta-cells. Some defense systems such as anti-oxidant vitamins, reduced glutathione, transport and storage proteins for binding divalent metal ions and antioxidant enzymes prevent injury caused by free radicals (Hensley, 2000).

In conclusion, diabetes mellitus and its complications is associated with free radical mediated cellular injury and lipid metabolism. Most probable causes for increased lipid peroxide level in diabetes include abnormal lipid metabolism, vascular complications, increased glycation of protein, peroxidation of apolipoproteins, a deficiency of antioxidant activity of superoxide dismutase and glutathione peroxidase (Blomhoff et al., 2006).

This study has shown the effect of ethanol extract of sweet almonds justifying the possibility of using the extract in management of diabetes mellitus and its complications.

## REFERENCES

- Allain CC et al., ((provide other authors name)) (provide topic) Clin.Chem. pp 20:470.
- Bendich A (1989) (provide topic) J. Nutr. 119:112-115.
- Drury RAB, Wallington EA, Cameron R (1967). Carlton's histological techniques. 4th ed. Oxford University, Press, NY. U.S.A. pp 279-280.
- Fossati P, Principe L (1982). ((provide other authors name)) Clin. Chem. Pp 28:2077.
- Friedline (2004). Introduction to Medicinal Herbalism. Oxford University Press, London, pp. 24-36.
- Hensley K, Robinson KA, Gabbita SP, Salsman S, Floyd RA. (2000). Reactive oxygen species cell signaling and cell injury. Free Radical Biol Med. 28:1456-1461.
- Jenkins DJ, Kendall CW, Josse AR, Saluatore S, Brighenti F, Augustin LS, Ellis PR, Vidgen E, Rao SV (2006). Almonds Decrease Post Prandial Glycemia, Insulinemia, and Oxidative Damage in Healthy Individuals. J. Nutr. 136 (12):2987-92.
- Lopes-Virella MF et al., ((provide other authors name)) (1972). (provide topic) Clin. Chem. pp18: 499.

- McGowan MW et al., ((provide other authors name)) (1983). (provide topic) Clin. Chem. Pp 29:538.
- Oberley IW (1988). Free radicals and diabetics. Free Radic Biolmed. 5:113-124.
- Piper SB (1996). Fatty Acid Synthesis and Transport Lipid Research, 12:609-610.
- Saltiel, A. R., and Kahn, C. R. (2001). Insulin signaling and the regulation of glucose and lipid metabolism. Nature. 414(6865):799-806.
- Sheetz, M. J. and King, G. L. (2002). Molecular understanding of hyperglycemia's adverse effect for diabetic complications. JAMA 288(20):2579-88.
- Ugochukwu, N. H., Bababy, N. E., Cobourne, M. and Gasset S. R. (2003). Effect of Gongronema latifolium extracts on serum lipid profile and oxidative stress in hepatocyets of diabetic rats. J. Bios. 28(1):1-5.