

Full Length Research Paper

Malrotation of the intestine in children in Port Harcourt, south-south Nigeria: Review of 26 cases

Nwankwo N. C. and Gboobo I.

Radiology Department, Faculty of Clinical Sciences, College of Health Sciences, University of Port Harcourt.
Surgery Department, Faculty of Clinical Sciences, College of Health Sciences, University of Port Harcourt.

Accepted 28 November, 2011

Malrotation of the gut especially the mid gut is rare and is a common cause of upper intestinal obstruction resulting in recurrent bilious vomiting early in life. Early diagnosis is important, so that corrective surgery can be performed immediately. The aim of the study is to review 26 cases of malrotation of upper gastro-intestinal tract managed by the authors over a 5 year period, note associated anomalies, and high light the importance of upper gastro-intestinal studies- barium meal in the diagnosis. This was a prospective study of 26 cases of malrotation of the intestine seen by the authors over a 5 year period in Port Harcourt, South-South Nigeria. Ages at presentation, modes of presentation and associated anomalies were reviewed. During this period about 189 abdominal paediatric surgeries were managed by the paediatric surgeon. Of these 26 (13%) were for malrotation of gastro-intestinal tract GIT. 16 (61.5%) were males and 10 (38.4%) were females. These patients presented with persistent bilious vomiting, abdominal distention, visible peristalsis in abdomen, frequent vomiting after food. Most mortality-5 (19%) was in the cases where diagnosis was delayed. Outcome was good in those presenting outside the neonatal period. Early detection/diagnosis of malrotation and prompt surgery is important and the emphasis should be to achieve this.

Keywords: Intestinal malrotation, barium meal and follow through, organogenesis.

INTRODUCTION

Malrotation is a rare cause of upper gastro-intestinal tract obstruction and was first reported by Mall in 1898 (Aiken et al., 2005). This is a developmental anomaly that affects the position and peritoneal attachments of the small and large bowels during organogenesis in fetal life and has been described as absent or incomplete rotation and fixation of the embryonic gut around the superior mesenteric artery (SMA) (Cassart et al., 2006; Parish and Hatley, 2006). In 1923, Dorr described the first clear clinical correlation with embryological observation (Aslanabadi, 2007). William Ladd also described a classic article on the treatment of malrotation, and introduced his surgical approach, "Ladd's procedure" which remains the bedrock of the practice today (Parish and Hatley, 2006).

We review 26 cases of malrotation of the intestine seen

in south-south Nigeria over a 5 year period.

MATERIALS AND METHOD

This was a prospective study of the 26 cases of malrotation of upper gastro-intestinal tract (GIT) managed by the authors over a five (5) year period from 2005 to 2010. Only six (6) of the patients had upper gastro-intestinal series –barium meal studies done and the diagnosis confirmed. Their ages, modes of presentation and associated anomalies were recorded over this period as presented in tables 1, 2, and 3. Radiographic images of one of the patients, photograph of the abdomen showing visible peristalsis and surgical images of three (3) of the patients are seen in figures 1,2,3,4 and 5. Figure 1 shows barium study images of malrotation of the duodenum with associated partial obstruction. Figure 2 is a photograph of one of the patients showing visible peristaltic waves in the abdomen. This is the hall mark of intestinal obstruction.

*Corresponding Author E-mail: emmynwankwo@yahoo.com

Table 1. Age at presentation

Age at presentation (in months)	Number	Percentage
0-6	9	34.6
7-12	5	19.2
13-18	4	15.3
19-24	3	11.5
25-30	2	7.6
31-36	2	7.6
>36	1	3.8
Total	26	100

Table 2. Modes of presentation.

Mode of presentation	number of patients	Percentage
Persistent bilious vomiting	20	76.9
Visible peristalsis	16	61.5
Upper abdominal distension	12	46.1
Failure to pass meconium	13	50
Frequent vomiting after feeds	10	38.4

Table 3. Associated anomalies.

Associated anomalies	Number	Percentage.
Duodenal atresia	8	44.4
Jejuno-ileal atresia	4	22.2
Renal agenesis	1	5.5
Volvulus	3	16.6
Intussusception	2	11.
Total	18	100

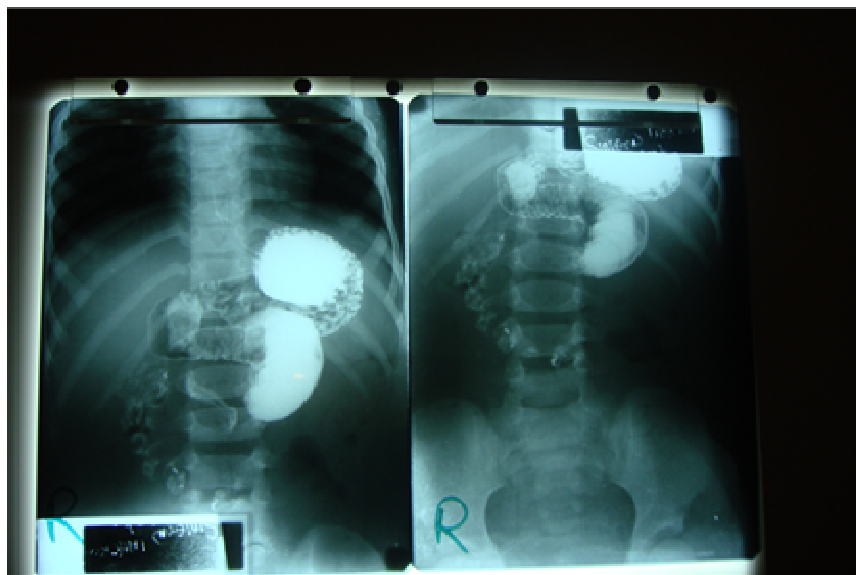
**Figure 1.** showing the malrotation of proximal small bowel and associated partial small bowel obstruction.

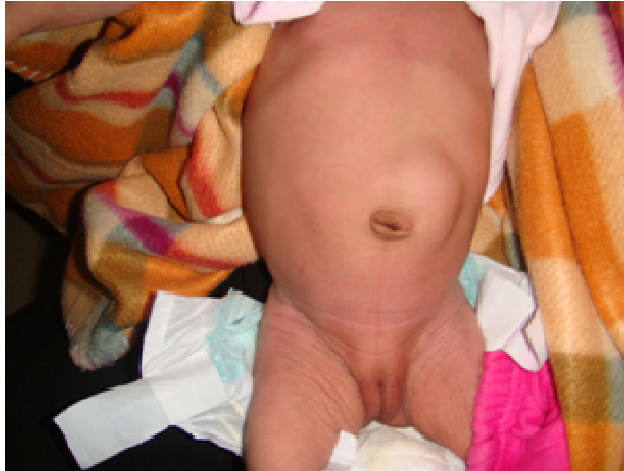

Figure 2. Visible peristalsis in the abdomen - the hall mark of intestinal obstruction.

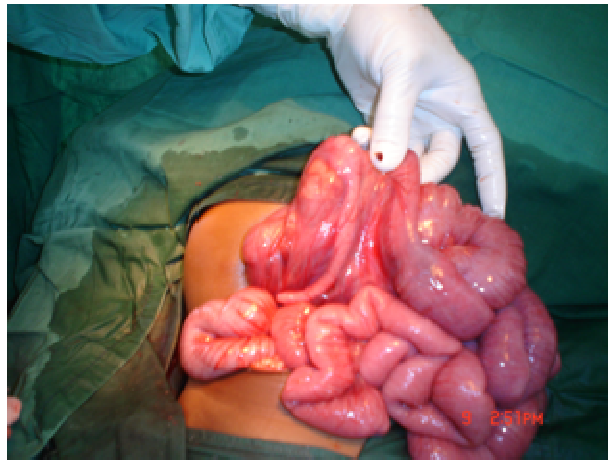


Figure 3. Non fixation of the ascending colon.

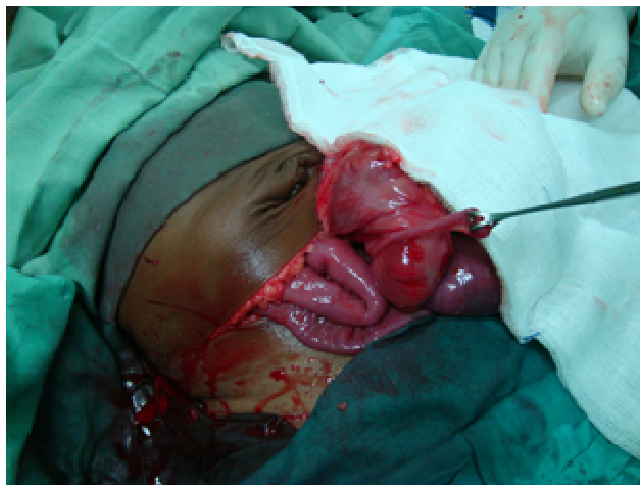

Figure 4. Abnormally located caecum and vermiform appendix in a patient that also had intussusception. Note the change in colour of the demonstrated gut.

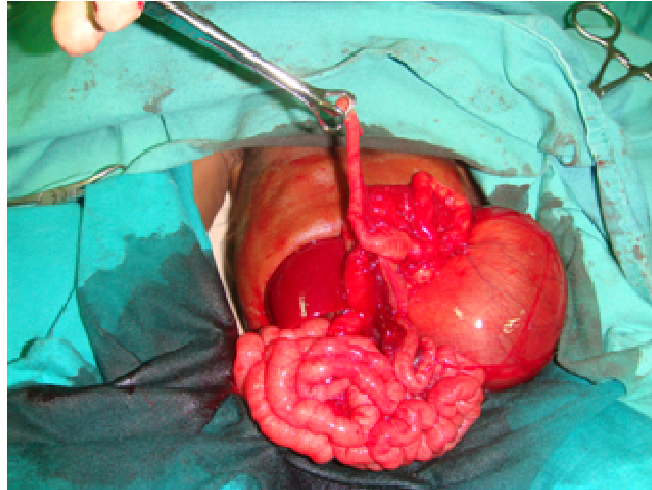


Figure 5. Non fixation of the ascending colon and abnormally located appendix.

RESULTS

In this study, the results show the largest age group at diagnosis was the 0-6 months with 9 patients (34.6%) and the lowest number was recorded at > 36 months and above 1 patient (3.8%).

The commonest mode of presentation was bilious vomiting which was seen in 20 patients (76.9%). Intussusception was seen in 2 patients (7.6%).

Duodenal atresia was the commonest associated anomaly with 8 patients (30.7%).

In the 26 cases, 18 patients (69.0 %) had associated congenital anomalies. 8 patients out of this (44.4%) had duodenal atresia, 4 patients (22.2%) had jejuno-ileal atresia (Table 3). Renal agenesis was recorded in 1 patient (5.5%).

DISCUSSION

Malrotation is a general term used to describe the result of abnormal embryonic gut rotation and fixation. This leads to an abnormally short base for the gut, mesentery and predisposes to twisting (volvulus).

Intestinal malrotation is a congenital condition that can have disastrous potentially fatal sequel. It is believed to occur in approximately 1 in 500 live births (Torres and Ziegler, 1993). Majority of the patients with this condition present in early infancy with bilious vomiting. If the diagnosis is not considered and prompt action taken to confirm or exclude malrotation the consequence can be catastrophic (Williams, 2007). 20 patients (76.9%) in this review presented with bilious vomiting. 16 patients (61.5%) had visible peristalsis in the abdomen.

Embryogenic gut forms by the second week of gestation. The gut develops from the yolk sac, becomes

internalized, forming a single short tube lined with endoderm by the third to fourth weeks, joined in its mid-portion to the yolk sac by the vitellointestinal duct. The surrounding layers of the mesoderm form the parietal peritoneum and mesenteries of the gut through which the blood vessels run. The gut is divided into three sections based on its arterial blood supply. The first which is the foregut is supplied by the celiac artery, midgut consists of the portion of the gut extending from the middle third of the duodenum (second part of the duodenum close to where the bile duct is inserted) to the mid distal transverse colon and is supplied by the superior mesenteric artery (SMA). The hindgut is supplied by the inferior mesenteric artery (IMA). SMA and IMA appear at the beginning of the 5th week and immediately afterwards the gut begins to elongate rapidly and becomes too large to be accommodated within the abdominal cavity.

By six weeks of gestation the loop of the gut herniates into the base of the umbilical cord.

The physiological herniation of the primitive gut is followed by further growth, parts of the gut loop elongating at different rates and the gut undergoes a series of three (3) 90^o anticlockwise rotational events. The first two anticlockwise rotational steps occur before the gut returns to the abdominal cavity at about 10 weeks gestation. The proximal small bowel enters first, undergoing a final 90^o anticlockwise turn. This 270^o anticlockwise rotation of the gut allows the duodenum to assume its normal C-shaped loop. Distal small bowel and the proximal colon enter last rotating a further 180^o anticlockwise so that the colon takes its normal peripheral location in the abdominal cavity. In the remainder of the gestation the caecum elongates to reach the right iliac fossa and the bowel becomes fixed. The second to the 4th parts of the duodenum ascending and descending colon

are fixed to the retro-peritoneum. The duodeno-jejunal (DJ) junction is fixed by the ligament of Treitz in the left upper quadrant and the transverse and sigmoid mesocolon are partially fixed leaving them with a small mesenteric attachment. The small bowel becomes fixed with a broad mesentery that extends from the ligament of Treitz in the left upper quadrant diagonally down to the ileocecal valve in the right lower quadrant. This broad mesenteric base stabilizes its position and prevents twisting or volvulus (Strouse, 2004; Applegate et al., 2006). Series of rotational events during gut development has been used to explain the normal and abnormal positioning of the gut. There is evidence from animal studies that the changes in the gut position may be the result of periods of differential growth (Miller et al 2003). It is important that the diagnosis of intestinal malrotation is made early enough and immediate action taken to save the patient. Fourteen (14) of the patients (53.8%) in this study presented at infancy and 20 (76.9%) had bilious vomiting.

Chirdan and Uba (2005) in their review of cases with intussusception in Jos, Nigeria over a three (3) year period had eight (44%) cases of abnormalities of intestinal rotation and fixation. In this study two (2) patients (7.6%) had intussusception confirmed at surgery. This number is small compared to what they recorded. Association of malrotation and intussusception has been referred to as Waugh's syndrome (Brereton et al., 1986; Breckon and Hadley, 2000; Inan et al., 2004).

Malrotation may occur as an isolated entity but usually is found in combination with other congenital conditions. Ford et al (1992) in their study had 31% of their patients presenting with isolated malrotation and volvulus. This is high when compared to 11% seen in this study. This difference may be due to the large number of cases in their study. It is important that the diagnosis of malrotation be made as early as possible. Upper gastrointestinal contrast study is the imaging reference standard for diagnosis of malrotation with or without volvulus (Strouse, 2004; Jamieson and Stringer, 2000; Berdon et al., 1970; Katz et al., 1987).

Barium sulphate or water soluble contrast medium (Gastrographin) can be introduced orally or via nasogastric tube. This is to demonstrate a normal duodenum and duodeno-jejunal (DJ) flexure position because this marks the position of the ligament of Treitz and if this is normally sited then malrotation is effectively excluded. The normal duodenum is composed of four (4) parts. The first part or the duodenal bulb (Cap) is intra-peritoneal and lies to the right of the spine at the same level as the pylorus. The second part descends to the spine, the third part crosses the midline to the left of the spine and the 4th part ascends to the DJ flexure which is located to the left of the spine at same level or higher than the duodenal bulb. In the lateral position the second to the 4th parts of the duodenum are posterior to the stomach as they are retro-peritoneal. Rarely GI contrast

study looks normal in the presence of malrotation: however there are also subtle abnormalities that can be misinterpreted as normal as well as normal variants that can be mistaken for malrotation (Applegate, 2006; Katz et al., 1987; Long et al., 1996). It is important that in equivocal cases experienced Pediatric Surgeon and Radiologist should review the patient and the images acquired from the upper GI series so that decisions on management can be taken without delay. One of our patients presented since infancy at different hospitals and had an average of four (4) admissions yearly for the four years of her life without been reviewed by a pediatric Surgeon and no radiological investigations was done until she was seen by the authors. GI series is difficult in children so care must be taken in the study. Excessive oral contrast can obscure the DJ, making diagnosis difficult. In equivocal cases final diagnosis is confirmed surgically. Relative distension of the stomach, proximal duodenum and proximal small bowel abnormally positioned in the right upper quadrant are highly suspicious of malrotation. Dilatation of multiple loops of bowel is an ominous sign as it may indicate volvulus with bowel ischemia (Buonomo, 1997).

Ultrasound can assess the relative positions of the SMV and SMA which are almost always abnormal in malrotation, but the vessels are often obscured by bowel gas so that it may not be possible to assess their relationship (Orzech et al., 2006). In the normal situation the SMV lies to the right of SMA. This relationship may be abnormal or reversed in malrotation with the SMV anterior or to the left of the SMA (Dufour et al., 1992).

Ultrasound can detect volvulus, the appearance of which is known as the "Whirlpool sign" (Pracros et al., 1992).

CONCLUSION

We have reviewed 26 cases of malrotation of the intestine. The presenting symptoms are not too different from reported cases/studies in the literature. All the cases involve the mid gut. Early detection and diagnosis of malrotation and prompt surgery is important and that is where the emphasis should be. The importance of well conducted upper gastro-intestinal series (Barium meal) is highlighted and high index of suspicion by experienced Pediatric Surgeon is important.

REFERENCES

- Aiken JJ, Oldham KT (2005). Malrotation. In Ashcraft KW, Holcomb GW, Murphy JP (eds) (2005). *Pediatric surgery*. Elsevier Saunders, New York, pp. 435-477.
- Applegate KE, Anderson JM, Klatte EC (2006). Intestinal malrotation in Children: a problem solving approach to the upper gastrointestinal series. *Radiographics* 26: 1485-500.
- Aslanabadi S, Ghalegolab-Behbahani A, Jamshidi M, Veisi P, Zarrintan S (2007). Intestinal malrotations: a review and report of thirty cases.

- Via Medica. *Folia Morphol.* 66(4): 277-282.
- Berdon WE, Baker DH, Bull S, Santulli TV (1970). Midgut malrotation and volvulus. *Radiol.* 96: 375-383.
- Breckon VM, Hadley GB (2000). Waugh's Syndrome: report of Six cases. *Pediatr Surg int* 16: 370-373.
- Brereton RJ, Taylor B, Hall CM (1986). Intussusception and malrotation in infants: Waugh's syndrome. *Br. J. Surg.* 73:55-57.
- Buonomo C (1997). neonatal gastrointestinal emergencies. *Radiol Clin. North Am* 35: 845-64.
- Cassart M, Massez A, Lingier P, Absil AS, Donner C, Avni F (2006). Sonographic prenatal diagnosis of malpositioned stomach as a feature of uncomplicated intestinal malrotation. *Pediatr Radio*, 36:358-360.
- Chirdan LB, Uba AF (2005). Association of midgut malrotation with intussusception. *Niger. J. Surgical res.* 7:1-2, pp159-161
- Dufour D, Dalaet MH, Dassonville M, Cadranel S, Perlmutter N (1992). Midgut malrotation, the reliability of sonographic diagnosis. *Pediatr Radiol.* 22:21-3.
- Ford EG, Senac MO (Jr), Srikanth MS, Weitzman JJ (1992). Malrotation of the intestine in children. *Ann. Surg.* 215(2):172-178.
- Jamieson D, Stringer D (2000). Small bowel. In: Babyn PS. *Pediatric gastrointestinal imaging and intervention.* 2nd ed. Hamilton, Ontario: Deker, pp. 311-332.
- Inan M, Basaran UN, Ayvaz S, Pul M (2004). Waugh's syndrome: report of two cases. *J. Pediatr. Surg.* 39:110-111.
- Katz ME, Siegal MJ, Shackelford GD, McAlister WH (1987). The position of mobility of the duodenum in children. *AJR Am. J. Roentgenol.* 148:947-51.
- Long FR, Kramer SS, Markowitz RI, Taylor GE, Liacouras CA (1996). Intestinal malrotation in children: tutorial on radiographic diagnosis in difficult cases. *Radiol.* 198:775-80.
- Miller AJW, Rode H, Cywes S (2003). Malrotation and volvulus in infancy and childhood. *Semin Pediatr Surg*; 12:229-36.
- Orzech N, Navorro OM, Langer JC (2006). Is ultrasonography a good screening test for intestinal malrotation? *Pediatr. Surg*; 41:1005-9
- Parish A, Hatley R (2006). Intestinal malrotation. In: *Pediatrics: Gastroenterology articles E-medicine* :<http://www.emedicine.com/ped/GASTROENTEROLOGY.htm>.
- Pracros JP, Sann L, Genin G, Tran-Minh VA, Morin de Finfe CH, Foray P, Louis D (1992). Ultrasound diagnosis of midgut volvulus: the "Whirlpool" sign. *Pediatr. Radiol.* 22: 18-20.
- Strouse PJ (2004). Disorders of intestinal rotation and fixation ("malrotation"). *Pediatr. Radiol.* 34:837-851.
- Torres AM, Ziegler MM (1993). malrotation of the intestine. *World J. Surg.*; 17:326-31.
- Williams H (2007). Green for danger! Intestinal malrotation and volvulus *Arch. Dis. Child Educ. Pract.* 92:ep91 doi10.1136/adc.116244.