

Case Report

Ischemic and non-ischemic central retinal vein occlusion in patients who received interferon-plus ribavirin

*Demir M, Guven D and Cinar S

Sisli Etfal Training and Research Hospital, Eye Clinic, Sisli/Istanbul/Turkey

Accepted February 21, 2013

The study aim to report three eyes of two patients with central retinal vein occlusion(CRVO) with treatment of interferon plus ribavirin in the two patients. Medical records of two cases that had central retinal vein occlusion retrospectively reviewed. This work was carried out in accordance to ethical guidelines of Declaration of Helsinki. The informed consent was obtained from the subjects. In three eyes of two patients occurred CRVO. One of CRVO was nonischemic and two were ischemic CRVO. Patients were received interferon(INF) plus ribavirin for treatment hepatitis C. Central retinal vein occlusion is serious problem in patients who under treatment of INF plus ribavirin.

Keywords: Central retinal vein occlusion, hepatitis C, interferon, ribavirin.

INTRODUCTION

Chronic infection with hepatitis C virus is estimated to affect almost 4 million people in the 170 million worldwide (Francis et al., 2002). Interferon (INF)-ribavirin combination therapy is a first line treatment and retinopathy occurs in 19–38% during treatment (Jain et al., 2001). Retinopathy is an ocular complication with a variable clinical course, usually benign and asymptomatic. However severe inflammatory and vascular intraocular disorders occurring during INF plus ribavirin treatment in hepatitis C infected patients. We report 3 eyes of 2 cases that received INF plus ribavirin associated CRVO. One of the cases INF-associated retinopathy consisting of a had bilateral CRVO (ischemic and nonischemic), and other case had only in one eye ischemic CRVO.

CASE 1

A 59-year-old male, treated for 24 weeks with pegylated interferon alpha(INF 100 mcg/weekly) plus ribavirin (1000 mg/day) for chronic hepatitis C and diagnosed 7 months previously, presented with blurred vision in the left eye

and sudden painless visual loss in the right eye. His general health did not show any other alterations. He had no diabetes, hypertension and other risk factors (cardiovascular or systemic). Ocular examination showed visual acuity of 0.001 in the right eye and of 0.4 in the left eye. The anterior segment was normal and intraocular pressure in the right eye was 12 mm Hg and in the left eye 14 mm Hg. Fundoscopy in the both eyes revealed retinal vessel tortuosity, cotton wool spots, multiple flame hemorrhages (Figure 1). Fluorescein angiography revealed delayed venous filling, large areas of ischemia in the right eye; retinal hemorrhages, periphlebitis, macular edema, CRVO (Figure 2). There was no macular serious ischemia in the left eye (Figure 2). Optical Coherence Tomography (OCT) showed macular thickening (427 μ m) in both eyes.

Interferon plus ribavirin were discontinued, and the patient was given 1 dose of intravitreal bevacizumab 1.25 mg injection to the right eye. His visual improvement in the right eye (0.001 to 0.05) and decreased macular thickness (322 μ m) in the right eye.

CASE 2

A 45-year-old female, treated for 16 weeks with INF (100 mcg/weekly) plus ribavirin (1000 mg) for hepatitis

*Corresponding Author E-mail: drmehmetfe@hotmail.com

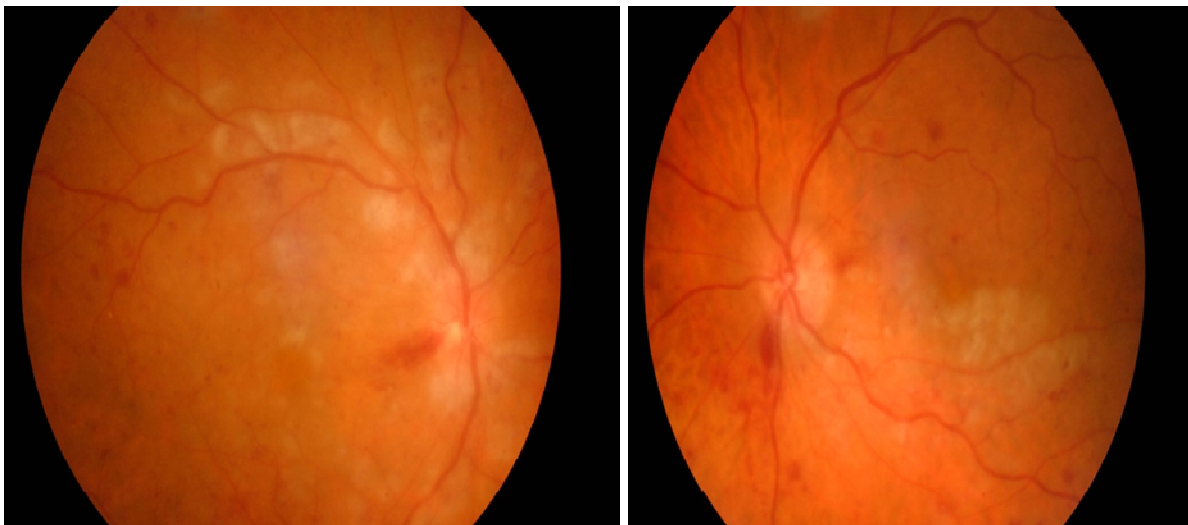


Figure 1. In the both eyes retinal vessel tortuosity, multiple flame hemorrhages, cotton wool spots at the posterior pole.

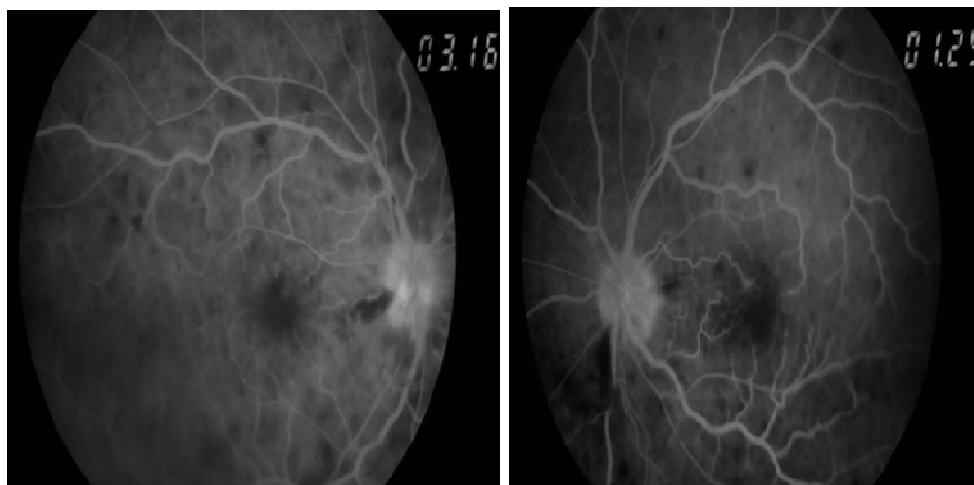


Figure 2. Fluorescein angiography shows delayed venous filling, ischemia eye, retinal hemorrhages, periphlebitis, macular edema, central retinal vein occlusion.

C and diagnosed 5 months previously, presented with loss of vision in the right eye for 3 days. Her general health did not show any other alterations. She had no hypertension and diabetes mellitus. Ocular examination showed visual acuity of 0.001 in the right eye and of 1.0 in the left eye. The anterior segment was normal in both eyes. Intraocular pressure in the right eye was 10 mm Hg and in the left eye 12 mm Hg. Fundoscopy in the right eye revealed retinal vessel tortuosity, cotton wool spots, multiple flame hemorrhages. Fluorescein angiography showed delayed venous filling, large areas of ischemia, retinal hemorrhages, periphlebitis, macular edema, CRVO in the right eye.

Central macular thickness was 536 μm in the right eye, and in the left eye was 235 μm .

Treatment was discontinued and the patient was given

2 doses of intravitreal bevacizumab 1.25 mg injection was performed with 1 month intervals to the right eye. Her visual improvement (0.001 to 0.05) and decreased macular retinal thickness (196 μm) in the right eye after 3 months from occlusion.

DISCUSSION

The most retinal side effects of treatment with INF plus ribavirin for hepatitis C are deep retinal hemorrhages and cotton wool spots. The less common side events of INF-ribavirin treatment are hyperemia of the disc, macular edema, retinal artery occlusion, central or branch retinal vein occlusion, Vogt-Koyanagi-Harada-like disease, panophthalmitis, anterior ischemic optic neuro-

pathy, retinal detachment, optic disc edema, neovascular glaucoma, vitreous hemorrhage (Okuse et al., 2006). Some case series suggest that in most patients, the clinical course of the disease is benign, asymptomatic, and without long-term consequences and therefore do not recommend any specific treatment; they only recommend the discontinuation of INF treatment in patients with severe manifestations or risk factors such as hypertension or diabetes mellitus. The side effect of interferon plus ribavirin treatment that cause severe loss of vision, fortunately is rare.

Similarities with some characteristics of diabetic and hypertensive retinopathy suggest an ischemic mechanism. Other authors suggest that immune complex deposits in the vessels lead to retinal capillary perfusion failure and the formation of cotton wool spots. Recent studies have found a linkage between INF-associated retinopathy and elevated serum levels of vascular endothelial growth factor (VEGF). The appearance of elevated VEGF levels is correlated with activation of angiogenesis, but its role in the pathogenesis of retinopathy is still unclear. Despite this similarities and suggest the exact pathophysiological mechanism due to which retinopathy develops is unclear. Interferon plus ribavirin related retinopathy mostly occur between 4-24

weeks after initiation of treatment (WHO Hepatitis C, 2002). Blurred vision was occurred in our cases in 16 and 24 week, respectively.

In our literature review, no case of bilateral CRVO (one eye was nonischemic, other ischemic). We presented two cases with CRVO during INF plus Ribavirin treatment for hepatitis C. The cases who presented here had no diabetes or hypertension. Bevacizumab was found as an effective agent in treatment of macular edema secondary to INF-ribavirin associated retinopathy.

REFERENCES

- Francis J, Ho I, Yannuzzi L (2008). Vitreous hemorrhage associated with interferon- α therapy for chronic hepatitis C. *Retinal Cases and Brief Reports.*;2:262–263
- Jain K, Lam WC, Waheeb S, Thai Q, Heathcote J (2001). Retinopathy in chronic hepatitis C patients during interferon treatment with ribavirin. *Brit. J. Ophthalmol.*; 85:1171–1173.
- Okuse C, Yotsuyanagi H, Nagase Y (2006). Risk factors for retinopathy as associated with interferon α -2b and ribavirin combination therapy in patients with chronic hepatitis C. *J. Gastroenterol.* 12:3756–3759.
- WHO Hepatitis C (2002). Global prevalence. *Wkly Epidemiol. Rec.*77:6.