

Full Length Research Paper

Inactivated autogenous vaccine associated with hemotherapy and application of *Thuya occidentalis* in the homeopathic treatment of canine oral papillomatosis - a case report

Dra. Rachel Siqueira de Queiroz Simões Marins^{1*}

Molecular Virology Laboratory, Virology Department, Oswaldo Cruz Foundation, Rio de Janeiro, Brazil, E-mail: marinsrsqs@hotmail.com

Accepted 1 March, 2011

Oral mucosal tropism also has been documented in humans, canines, primates and wild mammals. The effectiveness of combined therapy has shown greater success in the treatment of cutaneous papillomatosis and oral mucosal lesions. Autogenous vaccine, homeopathy and immunotherapy have been employed in the treatment of the cutaneous lesions and oral mucosal papillomatosis in different species. In the present study, we reported about papillomavirus clinical infection in canines. Based in the clinical analysis, the surgical removal from warts lesions biopsies on the oral mucosal of the canines was carried out. Oral biopsy specimens were confirmed papilloma by the histological examination and the canines were treated by electrocautery. One of them, showed warts again and association of therapy was indicated. Inactivated autogenous vaccine derived from fresh warts, immunotherapy and homeopathy with *Thuya occidentalis* by orally was applied. The regression of warts was observed after the application of combined treatment and the animal presented no new injuries during the two years of monitoring the clinic case.

Keywords: *canine papillomavirus*, oral mucosa lesions, homeopathy, hemotherapy, autogenous vaccine.

INTRODUCTION

Papillomaviruses research involved the study of cancer and molecular virology in the Veterinary and Human Medicine fields [Onions 1997]. *Human papillomavirus* (HPV) infections have been reported numerous lesions resulting several morphological types. Morphologically, mucosal lesions from *canine oral papillomavirus* (COPV) have been described similar to mucosotropic anogenital HPVs infections [Moore et al 2003]. Thus, COPV is useful model for the mucosal human PV infections and for the analysis of many aspects of viral pathogenesis.

The PV infection has induced increased mitotic activity in the epithelium. To investigate wart life cycle from papillomavirus infection, chronological series of lesions obtained from canines and bovines, can be considerate a good strategy to study about cellular immune response [Campo 1997, Nicholls et al 1999, Nicholls et al 2001]. Canine model has been used in the development of papillomavirus treatment, including L1 virus-like particles,

early genes, synthetic peptides, proteins fusion, recombinant viruses and DNA vaccines [1,2,3,5,6].

COPV is associated with oropharyngeal papillomatosis and cutaneous lesions in small wild dogs like coyotes and wolves. Different types of PV have been also documented in canines: *canine papillomavirus* type 2 (CPV-2) and *canine papillomavirus* type 3 (CPV-3) similar epidermodysplasia verruciformis disease [Tobler et al 2006], that does cluster on the common branch of the genus *Lambdapapillomavirus*. Molecular study showed the amplification of a novel papillomavirus isolated from a lesion of raccoon. Phylogenetically, the *Procyon lotor papillomavirus* type 1 (PIPV-1) is closely related to the COPV and also classified in the genus *Lambdapapillomavirus* [Rector et al 2005].

Oral papillomas also have been documented in humans, primates and in wild mammals: *Panthera leo persica papillomavirus* (PIPV) isolated from an oral lesion in the tongue of the lion [Sundberg et al 1996]. Recent studies

about papillomavirus evolution and genomic diversity have been detected. Novel papillomavirus was isolated from a papillomatous lesion on the oral mucosa of a polar bear and classified *Ursus maritimus papillomavirus type 1* (UmPV-1), does not cluster with other carnivore PV by phylogenetic analysis [Stevens et al 2006].

Combined therapy has shown greater success in the treatment of papillomavirus infections. Autogenous vaccine, homeopathy and immunotherapy have been employed in the treatment of the cutaneous lesions and oral mucosal papillomatosis in different species. The effectiveness of species-specific vaccine, homeopathy and herbal therapy in the treatment of bovine cutaneous papillomatosis has been documented [Marins et al 2005, Marins et al 2006], and satisfactory results were also supported by Indian researchers [Rai et al 1991, Prakash 1993].

In addition of the conventional drugs, alternative approaches include homeopathic medicine like *Thuya occidentalis*. *Thuya* is also known as *Cupressus arbor vitae*, was designated by Hahnemann as sycosis, the formation of wart-like excrescences upon mucous and cutaneous surfaces and is used in popular medicine to treatment of condyloma, warts, and papillomatous lesions. In the tincture has been comproved antibacterial activity against the strains of *Staphylococcus aureus* and *Bacillus subtilis* [Acosta et al 2000].

Thuya is effective in combating lesions of HPV and can be administered orally or applied in the skin injured. There are few scientific studies that evaluate the benefits and cytotoxic effects of tinctures sample from extract of this popular medicinal plant. In a study about the genotoxic effects of tincture, was not found to induce mutagenesis and early lesions in DNA [Valsa et al 2001]. The influence of *Thuya occ.* extract was also evaluated on the labeling of red blood cells and plasma proteins with technetium-99 m and the results showed a decrease in radioactivity in blood cells with the homeopathic drug [Oliveira et al 1996]. *Thuya occidentalis* mother-tinctures of different origins from Brazil and European countries were analyzed and the study comproved that there are some differences in the composition of these tinctures [Pozetti et al 1986].

In the present study, we investigated the papillomavirus clinical infection from warts lesions biopsies on the oral mucosal in canines. One of the animals involved in the study showed injury again and was treated with inactivated autogenous vaccine associated with hemotherapy and homeopathy.

MATERIALS AND METHODS

Anamnesis

A 5-year-old female and a 1-year-old male São Bernardo dogs were assisted at the veterinary clinic of the northern Rio de Janeiro State. The canines were submitted to anamnesis and clinical data

including use history of immunosuppressors drugs. In the clinical examinations were observed that both presented similar morphological lesions and clinically indicative of the oral mucosa papillomatosis lesions.

Conventional therapy with medications for warts and papillomas were administrated in short intervals time among applications in both canines. After intervention of specific drugs, only the mother showed signs of recovery. The offspring, male dog not castrated, with good physical condition weighing 42 kg showed resistant to conventional therapy. For the past 2 months after the therapy, the injuries were increasing and spread to all oral mucosa. New surgical removal of oral papillomas with electrocautery was performed. Shortly afterwards, the animal had further warts-like lesions on all the oral cavity.

Clinical evaluation

The canines were examined on the basis of clinical history for the presence of multiple oral wart-like lesions up to 4mm in size on the palate, tongue and the oral mucosa cavity (figure1). In clinical exam were not diagnosed the presence of cutaneous PV lesions. The lesions were multifocal, exophytic, circular, flat and others exhibited pedunculated aspect like cauliflower with pink color (figure 2). It was indicated the association of therapies with the use of homeopathic treatment with three applications of 5 mL of *Thuya occidentalis* 200 cH orally at intervals of 20 to 20 days. It was also recommended to use the hemotherapy with four applications at weekly intervals and autogenous vaccine was developed specifically for application of the clinic case.

Oral mucosa biopsy preparation

The animal was subjected to sedation and local anesthesia. After asepsis, biopsies of the oral cavity were taken followed by electrocautery. Part of the fragments of biopsies was to histological examination and for development of the vaccine.

Vaccination Protocol

Subcutaneous vaccination with an autogenous vaccine derived from homogenized fresh warts of affected dog was administrated. Formalin solution was added to inactivate the virus and doses of antibiotics to prevent bacterial contamination. The protocol was previously described [Marins et al 2005]. Booster vaccinations were delivered one week following clinical support, measurement and evaluation of papillomas regression.

RESULTS

During the treatment used, the regression of lesions [figure 3] and the persistence of part of them were observed until that canines oral papillomatosis showed regression of excrescences after the therapy associated applied [figure 4]. After one month of the treatment, the warts fell down and there were no clinical injuries in the oral mucosa of the canine. The animal was accompanied for a period of two years and new lesions were not found. No inflammatory reaction was observed after vaccination.

DISCUSSION

The effectiveness of different drug protocols was also demonstrated in the treatment of papillomatosis

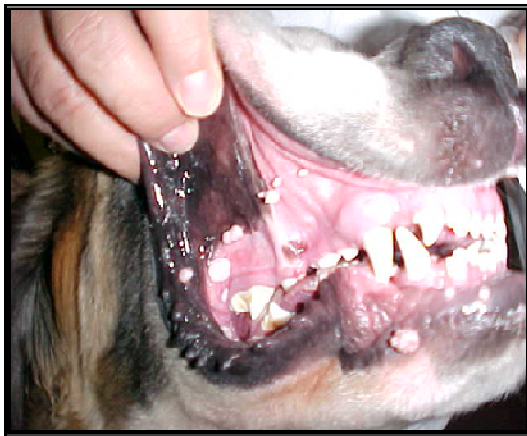


Figure1. Multiple oral wart-like lesions on the oral mucosa from male dog.



Figure 2. Small oral papillomas on the tongue and around of the oral cavity from dog.

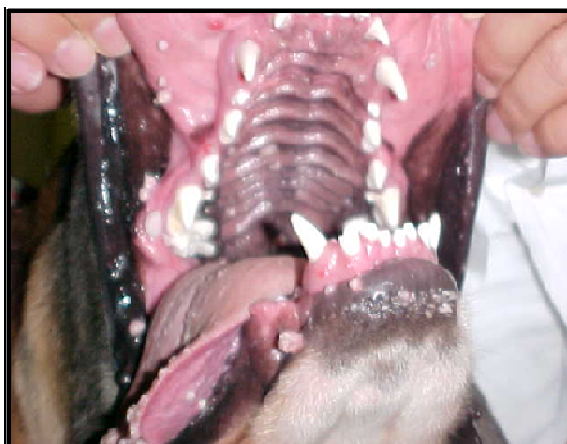


Figure 3. Presence of some papillomas during the treatment.

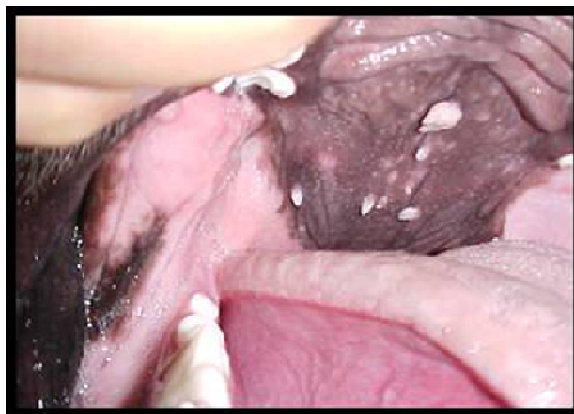

Figure 4. Recurrent papillomas lesions during the treatment on the palate.

[Veríssimo et al 2002] and papillomas were seen on the haired skin of the face, pinna and forelimbs [Nicholls et al 1999]. Analysis of material removed confirmed the presence of PV infection. The treatments of persistent papillomavirus infections are harder and induce to economic loss with excessive spending on drugs without therapeutic success. Cases of nonregressing canine papillomatosis have been reported after over 10 attempts included with autogenous vaccine and COPV L1 VLP vaccine [Nicholls et al 1999].

Studies reported severe or generalized papillomatosis in dogs immunosuppressed by drugs associated with deficiency of the immune system. Occasionally, persistent PV infection have been described how refractory to treatment. Associations similar are documented in humans immunosuppressed or immunodepressed like epidermal dysplasia verruciformis patients or by *Human Immunodeficiency virus* (HIV) infection [Campo et al 1996].

Our findings are compatible with the some authors in the use of *Thuya occidentalis* to the papillomatosis treatment [Marins et al 2006, Rai et al 1991, Prakash 1993]. However, this study the administration of the homeopathic treatment with Thuya combined with other therapies differs from protocol for the application of homeopathic drugs used by Indian authors. These administered daily for 8 to 10 globules of Thuya occ. 200 X by oral during a period of 21 days [Rai et al 1991, Prakash 1993]. Thus, there are few studies on the formulation of an aqueous solution administered by the oral route when associated with other unconventional alternative therapies for the treatment of recurrent wart-like lesions in canine oral papillomatosis.

CONCLUSION

The results demonstrated that the association of unconventional therapy was more effective in treatment

of persistent papillomas in the oral mucosal of canines and contribute with the understanding of the canine PV infections, but more studies about immunotherapeutic strategies will have to design to control persistent and recurrent papillomavirus infections.

With the several types of papillomavirus that affect the dogs, it is necessary to assess the best therapeutic method for each particular case, being a good option to choose the combination drugs, since the more pathogenic viral types have proven resistant to conventional drugs and there are not prophylactic vaccines commercially available until today.

REFERENCES

- Onions, D (1997). Papillomaviruses: progress for human and veterinary medicine. *Veterinary Journal*. 154: 171-172.
- Moore RA, Walcott S, White KL, Anderson DM, Jain S, Lloyd A, Topley P, Thomsen L, Gough GW, Stanley MA (2003). Therapeutic immunization with COPV early genes by epithelial DNA delivery. *Virology*. 314: 630-635.
- Campo MS (1997). Review bovine papillomavirus and cancer. *The Veterinary Journal* 154 (3): 175-188.
- Nicholls PK, Klaunberg BA, Moore RA, Santos EB, Parrys NR, Gough GW, Stanley MA(1999). Naturally occurring, non regressing Canine Oral Papillomavirus infection: host immunity, virus characterization and Experimental Infection. *Virology*, , 265: 365-374.
- Nicholls PK, Moore PF, Anderson DM, Moore RA, Parry NR, Gough GW, Stanley M (2001). Regression of canine oral papillomas is associated with infiltration of CD4+ and CD8+ lymphocytes. *Virol*. 283: 31-39.
- Dillner L, Heino P, Moreno-Lopez J, Dillner J(1991). Antigenic and immunogenic epitopes shared by human papillomavirus type 16 and bovine, canine, and avian papillomaviruses. *J. Virol*. 65: 6862-6871.
- Tobler K, Favrot C, Nespeca G, Ackermann M(2006). Detection of the prototype of a potential novel genus in the family *Papillomaviridae* in association with canine epidermodysplasia verruciformis. *J. Gen. Virol*. 87: 3551-3557.
- Rector A, Doorslaer KV, Bertelsen M, Barker IK, Olberg RA, Lemey P, Sundberg JP, Van Ranst M(2005). Isolation and cloning of the raccoon (*Procyon lotor*) papillomavirus type 1 by using degenerate papillomavirus-specific primers. *J. Gen. Virol*. 86: 2029 -2033.
- Sundberg JP, Montali RJ, Bush M, Phillips LG, O'Brien SJ, Jenson AB, Burk RD, Van Ranst M(1996). Papillomavirus-associated focal

- oral hyperplasia in wild and captive asian lions (*Panthera leo persica*). J. Zoo and Wildlife Medicine. 27: 61-70.
- Stevens H, Rector A, Bertelsen MF, Leifsson PS, Van Ranst M(2008). Novel papillomavirus isolated from the oral mucosa of a polar bear does not cluster with other papillomaviruses of carnivores. Veterinary microbial. 129: 108-116.
- Marins RSQS, Travassos CEPF, Pereira SRFG, Sales LG(2005). Effectiveness of species-specific vaccine in the treatment of bovine cutaneous papillomatosis. Brazilian Journal of Veterinary Medicine 27 (3): 130-132.
- Marins RSQS, Travassos CEPF, Pereira SRFG, Pereira MAVC, Vieira LFP(2006). Appraisal of efficiency of homeopathy and herbal therapy in the treatment of bovine cutaneous papillomatosis. Brazil. J. Veter. Sci. 13 (1): 10-12.
- Rai RB, Saha P, Srivastava N, Nagrajan V(1991) Bovine papillomatosis in Andaman and Nicobar. Indian Veter. J. 15: 71-72.
- Prakash R (1993). Homeopathic drug treatment of bovine cutaneous papillomatosis in a heifer: a case report. Indian Veter. J. 70 (11): 1055-1056.
- Acosta C M, García GD, Castro MI, Rodríguez JM, Crespo M (2000). Pesquisa homeopática. 15 (1): 67-75.
- Valsa JO, Felzenszwalb I(2001). Genotoxic evaluation of the effect of Thuya occidentalis tinctures. Brazil. J. Biol. 61 (2): 329-332.
- Oliveira JF, Braga A C, Avila AS, Fonseca LM, Guttilen B, Bernardo-Filho M (1996). Effect of Thuya occidentalis on the labeling of red blood cells and plasma proteins with technetium-99m. The Yale J. Biol. Med. 69 (6):489-494.
- Pozetti GL, Bernardi AC, Cabrera A (1980). Revista de homeopatia 145:9-11.
- Veríssimo ACC, Silva LAF, Viana Filho PRL, Matos ELS, Castro GR, Silva MAM, Fioravanti MCS, Andriolo J(2002). Avaliação da eficácia da cirurgia associada a diferentes protocolos medicamentosos no tratamento da papilomatose peniana bovina. Brazil. J. Veter. Sci. 9 (1): 266-268.
- Campo MS, Jarret WFH, O'Neil W, Barron RJ(1994). Latent papillomavirus infection in cattle. Research Veter. Sci. 56: 151-157.