



## Case Report

# Facial Hyperpigmentation in a Male Patient is the First Presentation of Addison's disease: Case report of Familial Addison's Disease and Review of Literature

**Khitam Al-Refu**

Assistant professor, Faculty of Medicine, Vice Dean of School of Medicine, Mu'tah University, PO Box 5, Karak, Mu'tah 61710, Jordan

E-mail: [Alrefukhi@yahoo.com](mailto:Alrefukhi@yahoo.com); Tel. 00962795050339

### ABSTRACT

**Addison's disease is a rare endocrine disease with skin and systemic manifestations. It is an emergency case and can be a life threatening disorder particularly in stressful situation. Early diagnosis and proper management is needed. This is a report of a case of autoimmune Addison's disease in a male patient presented to a dermatology clinic complaining of progressive facial hyperpigmentation and was not diagnosed previously with the disease. On screening of his family, one of his brothers was also diagnosed to have the disease. This case is presented to highlight the necessity to know this rare disease by dermatologist who treats patients presented with facial pigmentation.**

**Keywords:** Addison's disease, hyper pigmentation.

## INTRODUCTION

Addison's disease is a rare endocrine disease wherein the adrenal glands produce insufficient adrenal cortical hormones (Ten et al., 2001). Cortisol, the main hormone affected in the disorder is important in the body's ability to cope with stressful situation (Wolfgang, 1996). Addison's disease is a term restricted to primary adrenocortical insufficiency (most common autoimmune) (Ten et al., 2001; Wolfgang, 1996). Other secondary or tertiary causes of adrenocortical insufficiency are not included in the term 'Addison's disease'. A fraction of the patients with Addison's disease also present with or later develop other organ specific autoimmune disorders. These include hypothyroidism, diabetes mellitus, hypogonadism, vitiligo, and other disorders (Desmond and William, 2002; Derbergh et al., 1996).

Addison's disease symptom's are often non-specific and include fatigue, weakness, anorexia, nausea, abdominal pain, gastroenteritis, and mood disturbances. The most specific sign of the disease is the hyperpigmentation of the skin and mucosal surfaces (Desmond and William, 2002; Derbergh et al., 1996). In secondary and tertiary forms of Addison's, skin darkening does not occur.

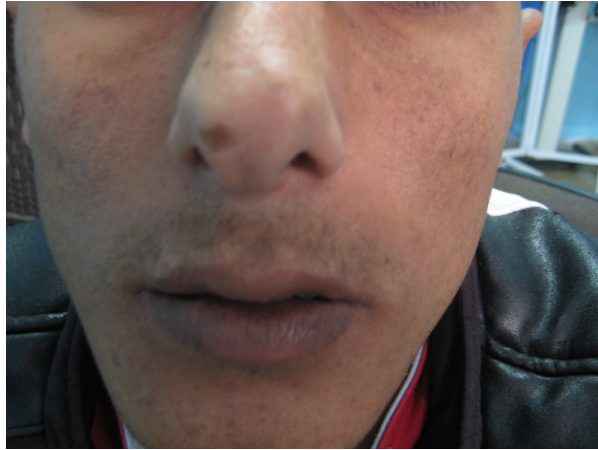Addison's disease is a well described clinical entity, in which early diagnosis and treatment may save the life of

the patient. The purpose of presenting this case is that this patient presented to my dermatology clinic complaining of facial hyperpigmentation and was not diagnosed before to have any medical problem. The patient was then diagnosed to have familial polyglandular autoimmune disease after referral him to an endocrinologist; the patient has adrenalitis, hypothyroidism and hepatitis. By screening his family, his brother also diagnosed to have Addison's disease. I present this case to highlight the necessity to know this urgent disease by dermatologist who treats patients presented with generalized facial pigmentation.

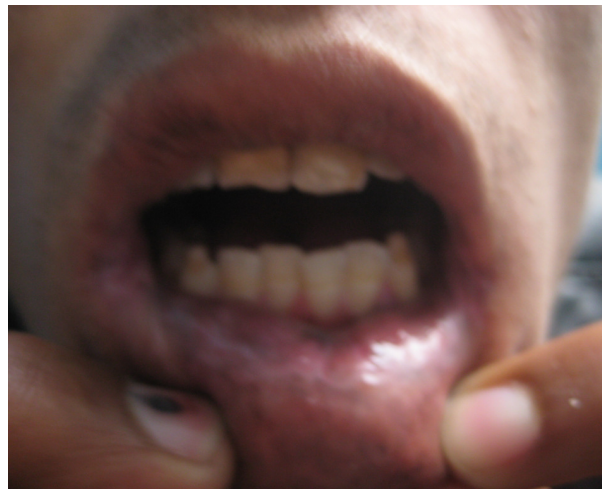
## Case Report

### The History

A 26-year-old male patient presented to Dermatology clinic/ Mu'tah University, Jordan, with increasing darkening of the face. He was treated before by private doctors as a case of chloasma and was given courses of bleaching agents (Hydroquinone 2 and 4%), but with no clinical response. Our patient is a Jordanian patient with skin type 4 (Fitzpatrick classification). The patient



**Figure 1.** The patient with Addison disease had facial hyperpigmentation.



**Figure 1.** Oral mucosa involvement with the hyperpigmentation

reported that this pigmentation was noticed mainly on face, but over several months, he noticed that this pigmentation involved other sites of his body, such as the chest and abdomen. For this history of pigmentation (which involve areas not exposed to the sun), full examination for the skin and mucous membranes of the patient was done and the possibility of Addison's disease or other causes of generalized hyperpigmentation could not be ruled out. There was negative history of taking drugs other than some analgesic for headache, negative history of dizziness and nausea or vomiting, but he gave history of easy fatigability that he adapted for. History of similar complaint of generalized hyperpigmentation by his brother (22 years).

Physical examination revealed a young male, with generalized hyperpigmentation especially on the face

(Figure 1), oral mucosa (Figure 2), palmar creases and knuckles. Main findings in the systemic examination were a pulse of 106 bpm, regular and small; blood pressure 100/60 mmHg supine and 90/50mmHg sitting. All other systems (including abdomen and chest examinations) were essentially normal.

#### **Laboratory investigations**

The patient was referred to endocrinologist to investigate him for Addison's disease. After making the required laboratory and radiological means diagnostic for the disease, the patient was diagnosed as a case of autoimmune Addison's disease. In addition to that, the patient also had autoimmune hypothyroidism (high TSH

level) and hepatitis (high level of transaminase (ALT & AST) and total bilirubin). His Brother (22 year, with similar distribution of pigmentation) also investigated and was diagnosed to have similar disease. Both of them were started on the usual treatment of Addison's disease including oral prednisolone and made remarkable recovery and improvement of their skin pigmentations within three-four weeks of treatment.

## DISCUSSION

Thomas Addison (1855) (Hiatt and Hiatt, 1997) first described the clinical features of primary adrenal insufficiency, which may result from a variety of pathological processes. The commonest causes of Addison's disease are autoimmune adrenalitis (Ten et al., 2001; Wolfgang, 1996). Patients with an autoimmune disease must be considered at risk for other autoimmune diseases (Desmond and William, 2002; Derbergh et al, 1996). S.derbergh et al (Derbergh et al, 1996) reported 40% of 97 patients with autoimmune Addison's disease had other clinically evident organ specific autoimmune disorders.

Addison's disease may manifest with diverse and non-specific clinical and/or biochemical features. The most specific sign of primary adrenal insufficiency is hyperpigmentation of the skin and mucosal surfaces (Burk et al., 2008; Lamey et al., 1985; Shah et al., 2005) associated with fatigue and weight loss. The skin hyperpigmentation, including areas not exposed to the sun; characteristic sites are skin creases (e.g. of the hands), nipples, and the inside of the cheek (buccal mucosa), also old scars may darken.

The manner of presentation of an illness can influence the ease with which a diagnosis is established. Had this patient been seen initially on a medical or an endocrine service, the diagnosis of Addison's disease would most probably have been made promptly.

However, the patient was seen in dermatology clinic complaining of just facial hyperpigmentation made the possibility of Addison's disease is unusual; the patient presented in this case was young patient who has no previous medical illnesses and not diagnosed previously to have Addison's disease. As demonstrated in this case, its wise to examine all patients presented with diffuse facial hyperpigmentation for presence of hyperpigmentation in sun-hidden areas and for the involvement of the oral mucosa with the hyper-pigmentation to rule out Addison's disease.

Primary adrenal insufficiency can be a life threatening disorder particularly in stressful situation, since cortisol secretion cannot be increased on demand at all. Early detection of the disease may reduce morbidity and mortality significantly in the patients with autoimmune polyglandular syndrome. Many syndrome diseases can be treated with respective substitution therapy.

## REFERENCES

- Burk CJ, Ciocca G, Heath CR (2008). Addison's disease, diffuse skin, and mucosal hyperpigmentation with subtle "flu-like" symptoms--a report of two cases. *Pediatr. Dermatol.* 25(2):215-8.
- Derbergh AS, Winqvist O, Norheim I (1996). Adrenal autoantibodies and organ specific autoimmunity in patients with Addison's disease. *Clin. Endocrinol.* 45: 453-60.
- Desmond Schatz A, William Winter E (2002) Autoimmune polyglandular syndrome II: clinical syndrome and treatment. *Endocrinol. Metab. Clin. N. Am.* 31: 339-52.
- Hiatt JR, Hiatt N (1997). The conquest of Addison's disease. *Am. J. Surg.* 174: 280-83.
- Lamey PJ, Carmichael F, Scully C (1985). Oral pigmentation, Addison's disease and the results of screening for adrenocortical insufficiency. *Br. Dent. J.* 158(8):297-8.
- Shah SS, Oh CH, Coffin SE (2005). Addisonian pigmentation of the oral mucosa. *Cutis.* 76(2):97-9.
- Ten S, New M, Maclaren N (2001). "Clinical review 130: Addison's disease 2001. *J. Clin. Endocrinol. Metab.* 86 (7): 2909-22.
- Wolfgang O (1996). Adrenal insufficiency. *N. Engl. J. Med.*; 335: 1206-12.

How to cite this article: AI-Refu K (2013). Facial Hyperpigmentation in a Male Patient is the First Presentation of Addison's disease: Case report of Familial Addison's Disease and Review of Literature. *J. Med. Med. Sci.* 4(10):387-389