

## Case Report

# Clinical and ultrasonographic correlation of post-coital isolated penile injury with corpus cavernosal haematoma: A case report

<sup>1</sup>Erondu Okechukwu Felix, <sup>2</sup>Ohuegbe Chyke Ihechikara, <sup>1</sup>Okoro Chinedum Richards, <sup>3</sup>Emmanuel Ehiwe

<sup>1</sup>Department of Clinical Imaging, Image Diagnostics, Port Harcourt Nigeria

<sup>2</sup>Ultrasound Unit, In Health, London United Kingdom

<sup>3</sup>Spire Harpenden Hospital Hertfordshire, United Kingdom

Accepted 21 June, 2010

**Penile fracture or male coital injury is a relatively uncommon condition. It is primarily the rupture of corpus cavernosum, with or without involvement of corpus spongiosum and the urethra. Using a case study approach, we present ultrasound findings of this rare and underreported urologic emergency suffered by a 32 year old male patient during copulation in a female dominant position. This is a case with the classical presentation of pain, detumescence, rapid penile swelling, right-sided deviation and isolated rupture of one corpus cavernosum with massive haematoma. The urethra and corpus spongiosum were spared. Ultrasound demonstrated the presence of isolated hematoma, integrity of the penile urethra as well as evidence of arterial compromise in this patient. Our study shows the importance of sonography as a readily available and non invasive modality in the management of this urologic emergency.**

**Keywords:** Penile fracture, coital injury, hematoma, corpus cavernosa, tunica albuginea.

## INTRODUCTION

Among the diverse spectrum of penile injuries such as penetrating injuries, penile amputation, penile soft tissue injuries and penile fractures, penile fracture is primarily a rupture of the corpus cavernosum, which occurs when the penis is in erectile position (Rosentein and McAninch, 2004; Mohapatra and Kumar, 1990). The rupture can also affect the corpus spongiosum and the urethra (de Mendonca et al, 2009; Jagodic et al, 2007; Golijanin et al, 2006).

With symptoms similar to penile bruising or contusion, the condition is characterized by a popping of the penis, presence of pain, detumescence, skin hematoma and penile deviation (de Mendonca et al, 2009; Fergany et al, 1999; Karadeniz et al, 1996; Golijanin et al, 2006; Eke, 2002; McEleny et al, 2006 ).

Because it is a superficial structure, the penis is ideally suited to ultrasound imaging. Color Doppler techniques when combined with pharmacologic duplex ultrasonography will provide an objective, minimally invasive evaluation of penile structure and haemodynamics at relatively low cost (Golijanin et al,

2007; Wilkins et al, 2003).

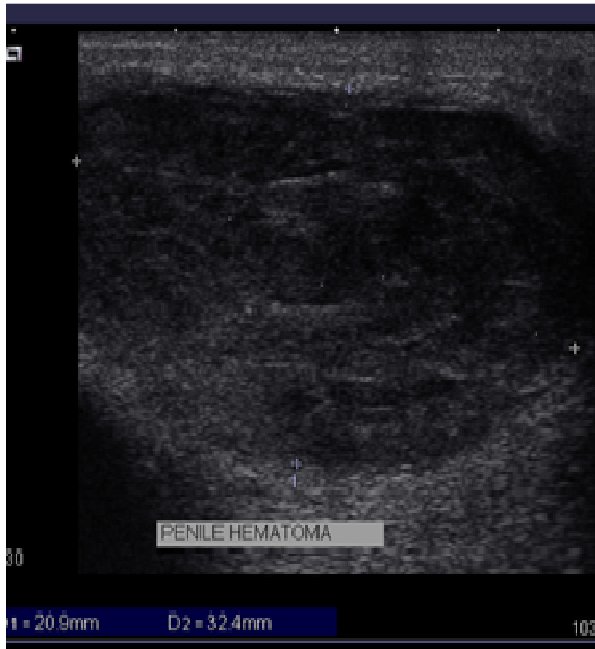## CASE REPORT

A 32 year old man presented for penile ultrasound following an injury sustained during copulation in the female dominant position. Patient reported that he experienced a sudden cracking sound with pain; followed by a limping and deviation of the penis to the right side. Our initial physical examination of the penis prior to scan revealed a tender, swollen penis. No previous history of dysuria, haematuria, or urethral discharge was reported prior to the incident.

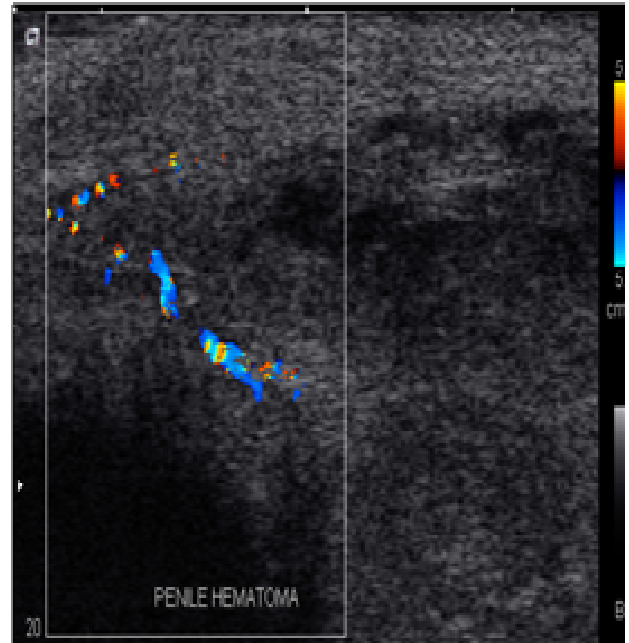
## RESULTS

Using an Acuson X500, X-class Siemens Ag Germany ultrasound scanner with a 12.5 MHz high frequency transducer, ultrasound scan revealed a compressible area of hematoma collection on the penis. A heterogeneous semi-fluid mass (20.9 x 32.4) mm was noted in the left corpus cavernosum (Figure 1). Colour

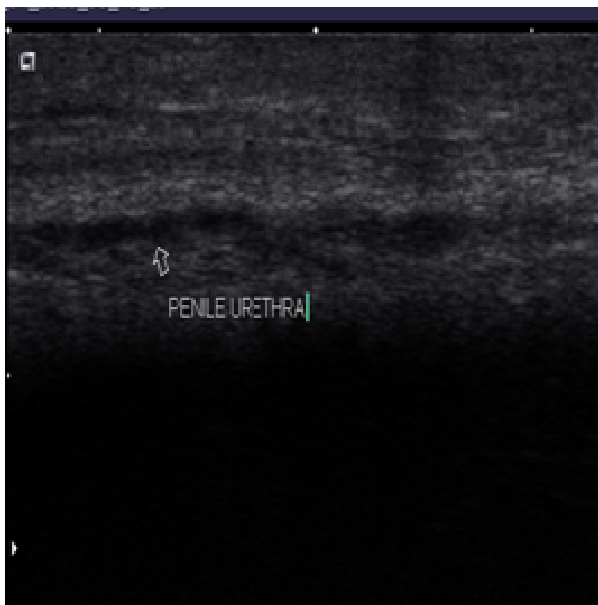\*Corresponding author E-mail: okerons@yahoo.com



**Figure 1** Hematoma in the Left Corpus Cavernosum



**Figure 2.** Doppler image showing disruption of cavernosal arterial blood flow due to injury



**Figure 3.** Penile Urethra and Corpus Spongiosum appear intact

Doppler interrogation revealed significant disruption of cavernosal blood supply in the affected region (Figure 2). Scanning over the glans penis, corpus spongiosum and urethra were unremarkable (Figure 3). Ultrasound diagnosis of a left corpus cavernosal hematoma with associated arterial compromise was made. Immediate treatment including conservative and/or surgical

intervention was recommended. No further laboratory investigations, radiological studies such as urethrography or urethroscopy were performed on this patient.

### Treatment

Conservative management was administered after our patient initially declined surgical intervention. Non-operative therapy including the use of cold compression, pressure dressing, penile splinting, and anti-inflammatory medications were administered.

Although ultrasound scan of the urethra indicated no urethral injuries, a supra pubic urinary deviation with a catheter to facilitate any latent urethral injury was undertaken 3 days after the ultrasound investigation. This was indicated because the patient later complained of dysuria.

The swelling regressed over a 7 day period, leaving a lump and slight right-sided deviation. Normal urination returned after this period. Further imagings such as urethroscopy, urethrography or MRI were not undertaken.

### DISCUSSION

Penile fracture is a urologic emergency which may require conservative and/or surgical intervention. Literature report indicates that prolonged delay in seeking medical treatment and non-surgical conservative management has resulted in 10%-50% complication

rates such as pain during copulation, lateral curvature and damage to the urethra (He et al, 2007). While it is associated with copulation in the female dominant position with the penis slipping out of the vagina and striking the perineum or the pubic symphysis, other potential causes include industrial accidents, masturbation and gunshot wounds (He et al, 2007). Penile manipulation to achieve gradual reduction in swelling, mechanical trauma from hastily removing or applying clothing when the penis is erect, forced bending or turning over in bed have also been reported with this condition (Kahvecioglu et al, 2009).

Penile fracture is classically a disruption of the tunica albuginea of one or both corpora cavernosa when the penis is in hard erect position (Rosentein and McAninch, 2004; Mohapatra and Kumar, 1990). It can be accompanied by partial or complete urethral rupture or by injury of the dorsal nerve and vessels (Haas et al, 1999). Urethral trauma is more common when both left and right corpora cavernosa are injured. Our result showed disruption of the left corpus cavernosum, leading to cavernosal haematoma with no urethral damage.

Although there is no bone or calcification in the normal penis which could predispose it to fracture, conservative management of it includes the use of cold compression, pressure dressings, penile splinting and the use of anti-inflammatory drugs. This line of management was undertaken in our patient under review. Similarly, the use of fibrinolytics and suprapubic urinary diversion for delayed repair of urethral injuries has also been reported to relieve the urethra in cases of urethral involvement (McEleny, 2006). It was important to note that while initial ultrasound reported no urethral injury as indicated in Fig3, our patient later developed signs of dysuria 3 days after the initial ultrasound scan. As indicated above, this condition was relieved with the use of the supra pubic catheter. This goes to confirm our literature findings as indicated in patients with urethral and corpus spongiosum involvement (Rosenstein and McAninch, 2004)

Penile complications from urethral abscess, nodule formation and lateral curvature which may lead to painful erection and erectile dysfunction, corporourethral fistula, arteriovenous fistula, and fibrotic plaque formation are also further complications associated with this disease (Summerton et al, 2005)

As indicated in our report, no information was available on the erectile capabilities of our patient. However, a resultant lump on the left side with a right lateral penile deviation of the penis was reported. This may have been avoided if the patient had not declined the surgical intervention which has the tendency to produce better outcomes, increased patient satisfaction with little or no complications.

From the above, the invaluable contributions of ultrasound as a readily available, safe, inexpensive and non-invasive modality cannot be argued. It was used in the first instance to delineate the extent of injury suffered

by the patient. This may otherwise have been difficult or impossible if other imaging modalities such as MRI, invasive urethrogram or urethroscopy had been undertaken (Wilkins et al, 2003). Similarly, the use of ultrasound allows follow-up assessment of the injury to be undertaken with minimum physical and psychological distress to the patient (Golijanin et al, 2007; He et al, 2006; Kahvecioglu et al, 2009). Other advantages such as reduced investigation time, and concurrent assessment of the arterial as well as venous blood supply to the injured penis may not have been possible with other imaging modalities.

## Conclusion

A wide range of possible causes account for the origin of penile fractures. Trauma to the erect penis during sexual intercourse in the female dominant position is widely known as its chief cause. Using ultrasound imaging as a readily available and inexpensive imaging modality, this emergency urologic condition can both be diagnosed and routinely followed up to ascertain the site and extent of fracture of the corpus cavernosum with or without involvement of the spongiosum, urethral injury, repair or complication. Ultrasound is capable of diagnosing post-traumatic hematomas. These may not otherwise be possible with other imaging modalities which are generally more financially expensive, and may cause both physical and emotional discomfort to the otherwise tender penis.

## REFERENCES

- De Mendonca RR, Bicudo M C, Sakuramoto PK, Bezerra C A, Pompeo A C, Wroclawski E.R (2009). Isolated anterior urethral trauma in man after coitus. A case report. *Einstein*. 7(4 pt 1): 503-505.
- Eke N (2002). Fracture of the penis *Br. J.Surg.* 89: 555-565.
- Fergany A F, Angermeier KW, Montagne DK (1999). Review of Cleveland clinic experience with penile fracture *Urology*. 54(2):352-355
- Golijanin D, Singer E, Davis R, Bhatt S, Seftel A, Dogia V (2007). Doppler evaluation of erectile dysfunction – part 2. *Int. J. Impot. Res.* 19(1):43-48.
- Haas CA, Brown SL, Spirnak JP (1999). Penile fracture and testicular rupture. *World J. Urol.* 17: 101-106.
- He ZJ, Cheng M, Zhang K, Jin J (2006). The value of dynamic color duplex scanning in the diagnosis of erectile dysfunction. *Zhonghua Nanke Xue.* 12(1):62-65
- Jagodic K, Erklavec M, Bizjak I, Poteko S, Jagodic H K (2007). A case of penile fracture with complete urethral disruption during sexual intercourse: A case report. *J. Med. Case Reports.* 1:14
- Kahvecioglu N, Kurt A, Ipek A, Yazicioglu KR; Akbulut Z (2009). Predictive value of Cavernosal penile systolic velocity in the flaccid penis. *Adv. Med. Sci.* 54(2):233-238
- Karadeniz T, Topsakal M, Ariman A, Erton H, Basak D (1996). Penile fracture: Differential diagnosis, management and outcome. *Br. J. Urol.* 77(2):279-281.
- McEleny K, Ramsden P, Pickard R (2006). Penile fracture. *Nat clin pract. Urol.* 3(3):170-174
- Mohapatra TP, Kuma S (1990). Reverse Coitus. Mechanism of urethral injury in male partner *J. Urol.* 144(6): 1407-1408.

Rosenstein D, McAninch JW (2004). Urologic emergencies. *Med Clin North Am.* 88:495-518.

Summerton DJ, Campbell A, Minhas S, Ralph D J (2005). Reconstructive surgery in penile trauma and cancer. *Nat. Clin. Pract. Urol.* 2:391-7.

Wilkins CJ, Sriprasad S, Sidhu PS (2003). Color Doppler ultrasound of the penis. *Clin. Radiol.* 58(7): 514-523.