



Case Report

A patient with Glioblastoma Multiforme who improved after taking citric acid orally

Alberto Halabe Bucay

Hospital Angeles Lomas, Mexico

Author email address: doctorhalabe@hotmail.com

ABSTRACT

The fact that citric acid is effective as a cancer treatment is already published, more than 6 years ago, in this article I present the case report of a male patient diagnosed with glioblastoma multiforme who totally improved after taking citric acid orally as the only antineoplastic treatment that he received.

Keywords: Citric acid, Cancer, Glioblastoma multiforme, Antineoplastic

INTRODUCTION

I published the medical hypothesis that citric acid, as being the natural inhibitor of glycolysis, would be effective as a cancer treatment since March, 2007 in the Journal Medical Hypothesis, from Elsevier (Halabe Bucay A, 2007). Two years and two months later, on May, 2009, I published in the same journal the first case of a patient with cancer who improves only with citric acid as his antineoplastic treatment, as a demonstration of the hypothesis previously published (Halabe Bucay A, 2007) the patient is a 15 years old boy who had terminal cancer, medullary thyroid cancer as part of a multiple endocrine neoplasia type 2B, a lethal congenital disease when patients affected gets 10 years old (Gertner ME and Kebebew E, 2004), this is the first article published in History about a patient with cancer effectively treated with citric acid (Halabe Bucay A, 2009), and 9 months later, on February, 2011, the second patient with terminal cancer, peritoneal mesothelioma who improves again, only with citric acid as his treatment, was published (Bucay AH, 2011), peritoneal mesothelioma, when is diffused as this patient presented, has a very bad prognosis (Mirarabshahii et al., 2012).

CASE REPORT

In this article I present the case report of a patient with glioblastoma multiforme, the patient is a 45 years old male who underwent surgery on December 11, 2012

after being diagnosed with a tumor mass in right parietal region detected by magnetic resonance imaging (MRI) (Figure 1), the pathology report performed by a specialist was of a grade IV astrocytoma, that is described as glioblastoma multiforme according to WHO classification, in the first surgery was only possible to perform a partial resection of the tumor, it measures 1.5 x 1.5 x 0.6 cm. and in the MRI performed 3 days after surgery persisted the tumor (Figure 2), the patient began taking citric acid orally on December 19, 2012, he only received levitracepam, prednisone, which was suspended one month later and diphenylhydantoin, for prevention of seizures, in the MRI of February 5th, 2013, there was no evidence of the tumor (Figure 3), and the general conditions of the patient were excellent.

DISCUSSION

The hypothesis that citric acid is effective as a cancer treatment has been demonstrated with these three (3) unquestionable cases (Halabe Bucay A, 2009 and Bucay AH, 2011), including this case report of a patient with glioblastoma multiforme, one of the most serious types of cancer (Omuro A and DeAngelis LM, 2013).

A lot of people knew the improvement of this patient, and the evidence that citric acid is effective as a cancer treatment is very well documented in internet and very easy to find, that is why the possibility that large number

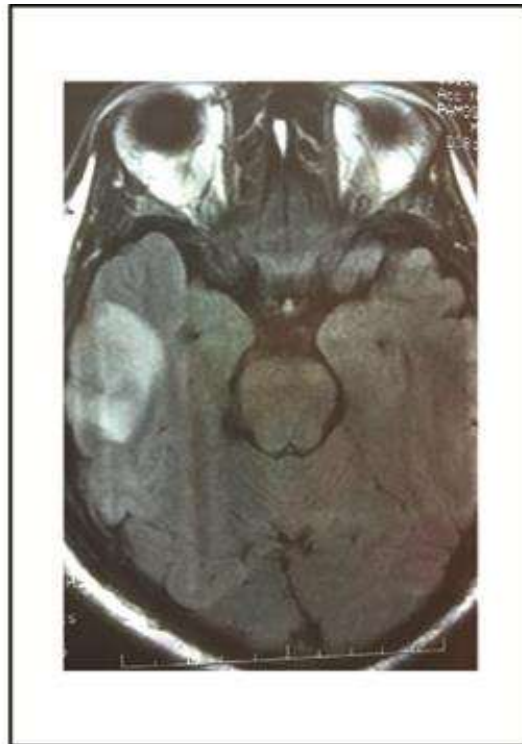


Figure 1.
NMR before surgery.

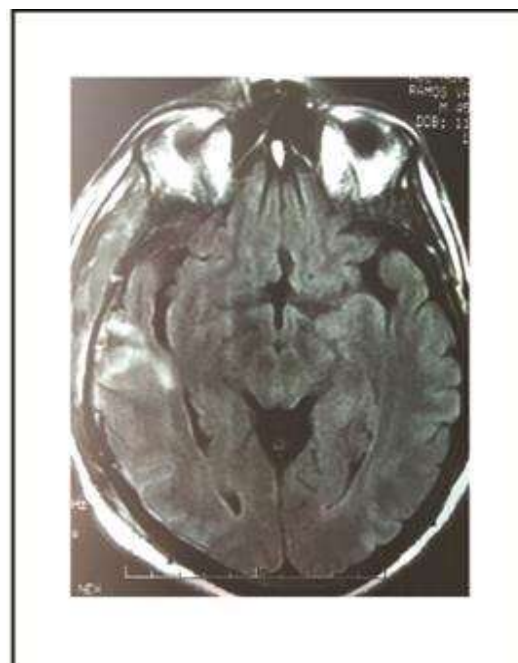


Figure 2.
NMR after surgery

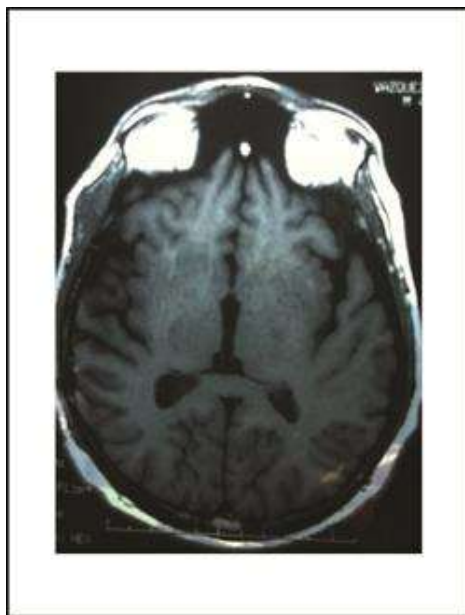


Figure 3.
NMR after treatment with citric acid.

of patients with different types of cancer worldwide are taking citric acid orally without notification is very high (Halabe Bucay A, 2013).

CONCLUSION

Finally the patient described in this article presented fatal complications after a second surgery performed unnecessarily 9 months after the initial diagnosis, but the fact that he had a glioblastoma multiforme and that it completely disappeared after 6 weeks of taking citric acid orally is unquestionable.

REFERENCES

- Halabe Bucay A (2007). The biological significance of cancer: Mitochondria as a cause of cancer and the inhibition of glycolysis with citrate as a cancer treatment. *Med Hypothesis*. 69(4):826-828.
- Gertner ME, Kebebew E (2004). Multiple endocrine neoplasia type 2. *Curr Treat Options Oncol*. 5(4):315-25
- Halabe Bucay A (2009). Hypothesis proved... citric acid (citrate) does improve cancer: A case of a patient suffering from medullary thyroid cancer. *Med Hypothesis*. 73(2):271.
- Bucay AH (2011). Clinical report: A patient with primary peritoneal mesothelioma that has improved after taking citric acid orally. *Clin Res Hepatol Gastroenterol*. 35(3):241
- Mirarabshahii P, Pillai K, Chua TC, Pourgholami MH, Morris DL (2012). Diffuse malignant peritoneal mesothelioma- an update on treatment. *Cancer treat Rev*. 38(6):605-612
- Omuro A, DeAngelis LM (2013). Glioblastoma and other malignant gliomas: A Clin. Rev. *JAMA*. 310(17):1842-1850
- Halabe Bucay A (2013). The possibility that large number of patients with cancer worldwide are taking citric acid orally is very high. *Glob. Adv. Res. J. Pharm. Pharm. (GARJPP)*. 2(1):001.
- How to cite this article: Alberto Halabe Bucay (2015). A patient with Glioblastoma Multiforme who improved after taking citric acid orally. *Int. Res. J. Basic Clin. Stud*. 3(1):35-37